



# A rare case of *Moraxella lacunata* producing combined native mitral and aortic valve endocarditis

Dasari S<sup>1</sup>, Shetty RK<sup>2</sup>, Devasia T<sup>2</sup>

1. Department of Medicine, Kasturba Medical College, Manipal

2. Department of Cardiology, Kasturba Medical College, Manipal

---

## CASE REPORT

---

Please cite this paper as: Dasari S, Shetty RK, Devasia T. A rare case of *Moraxella lacunata* producing combined native mitral and aortic valve endocarditis. AMJ 2011, 4, 7, 386-388

<http://doi.org/10.21767/AMJ.2011.718>

---

### Corresponding Author:

Sowjanya Dasari

Department of Medicine

Kasturba Medical College, Manipal 576104

Manipal University

Email: [dasaris2001@yahoo.com](mailto:dasaris2001@yahoo.com)

---

## Abstract

---

We describe a case of infective endocarditis due to *Moraxella lacunata* involving the native mitral and aortic valves, complicated by cerebral emboli and resultant hemiparesis. The patient was treated with ceftriaxone and gentamicin and improved. This appears to be the first case reported in the medical literature of native multivalvular endocarditis produced by this rare organism.

### Key Words

*Moraxella lacunata*, multivalvular endocarditis, native valve endocarditis, cerebral emboli, modified Duke's criteria

---

## Background

*M. lacunata* is a non-fermentative Gram-negative coccobacillus, belonging to the *Moraxella* family. These bacteria constitute part of the normal flora of the respiratory and genital tracts. Of the various species of *Moraxella*, only *M. catarrhalis* is strongly associated with systemic infection,

especially in patients with chronic pulmonary disease. Although well-known as a cause of conjunctivitis, keratitis and chronic sinusitis, *M. lacunata* is rarely associated with severe infections such as endocarditis.

### Case details

A 32-year-old housewife diagnosed previously with multivalvular rheumatic heart disease, on irregular prophylaxis with penicillin, was admitted with a history of high grade fever and arthralgias for the past three weeks.

On examination, she was febrile and had mild pallor but exhibited no other signs of infective endocarditis. Cardiac examination revealed a pansystolic murmur at the apex and an ejection systolic murmur at the aortic area, with corresponding systolic thrills. Routine laboratory tests showed mild anaemia (Haemoglobin: 10.1 gm/dL), neutrophilic leucocytosis (17,200 cells/cu.mm; 87% neutrophils, 5% bands) and an elevated ESR (124 mm in first hour). Transthoracic echocardiography confirmed the presence of mitral regurgitation and aortic stenosis, as well as mitral stenosis and aortic regurgitation. Two vegetations were seen respectively on the aortic and mitral valve leaflets (see Figures 1, 2 and 3).

Five blood cultures were drawn and sent over the next 96 hours. Pending results, the patient was treated empirically with intravenous ceftriaxone and gentamicin. Despite early institution of therapy, she developed right-sided hemiparesis on the fifth day of hospital stay. CT imaging revealed an acute infarct in the left lentiform nucleus (see Figure 4).

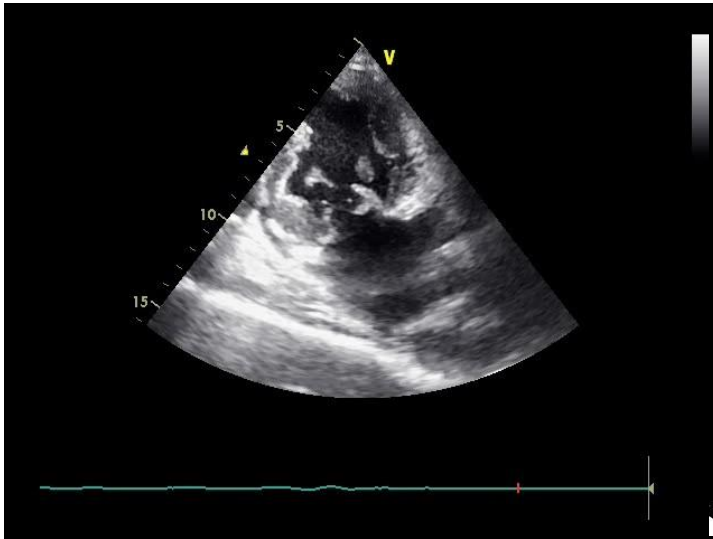


Figure 1: Transthoracic echocardiography (apical two chamber view) showing mitral leaflet vegetations.

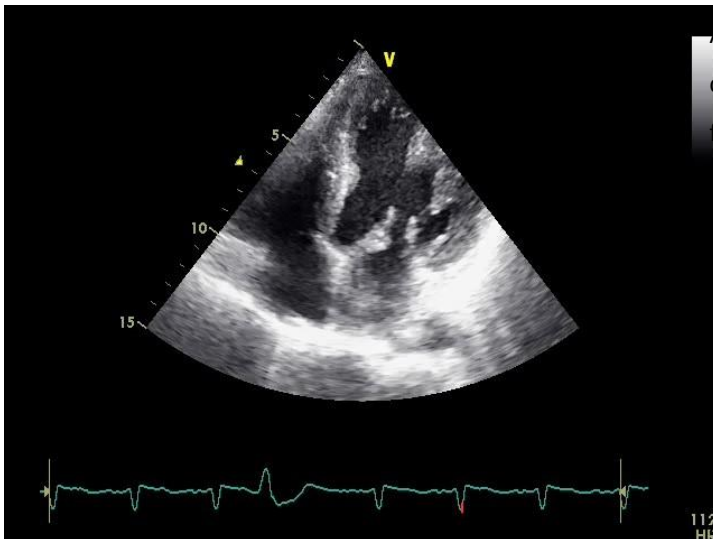


Figure 2: Transthoracic echocardiography (apical four chamber view) showing mitral leaflet vegetations.

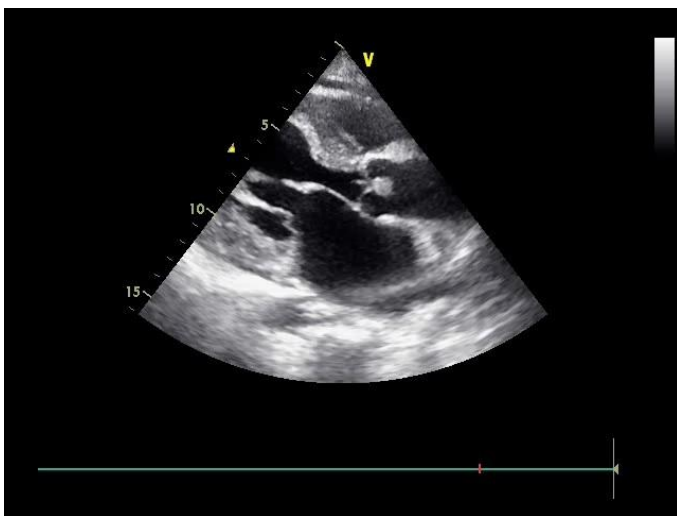


Figure 3: Transthoracic echocardiography (parasternal long axis view) showing aortic leaflet vegetations.

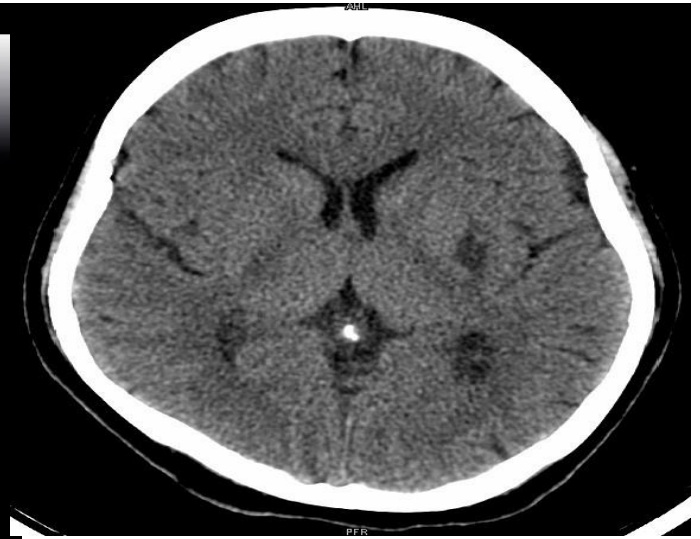

Figure 4: CT head showing an acute infarct in the lentiform nucleus of the left basal ganglia.

A Gram-negative bacillus was isolated from all five blood cultures, ruling out the possibility of a contaminant. On further analysis, it was found to be catalase and oxidase positive. It was identified by the API 20NE system (Bio Merieux-France) as *M. lacunata*. Sensitivity testing by the disk-diffusion method demonstrated sensitivity to ampicillin, ceftriaxone and aminoglycosides; the same antibiotic regimen was therefore continued for the next six weeks.

Although serial transthoracic echocardiograms were suspicious of a root abscess, this possibility was ruled out by transesophageal echocardiography. Furthermore, the patient responded clinically with gradual reduction of her fever. Her hemiparesis also improved with only minimal residual deficits. She was kept on maintenance penicillin prophylaxis for rheumatic heart disease.

### Patient consent

Signed informed consent was given by the patient for publication of material pertaining to this case.

### Discussion

Although frequently associated with conjunctivitis, especially in the paediatric age-group<sup>1</sup>, *M. lacunata* is an exceedingly rare cause of endocarditis. Other unusual



manifestations include acute meningitis, arthritis and septicaemia.<sup>2</sup>To date, only eight cases of endocarditis have been reported in the medical literature. These were summarised by Maayan H et al<sup>3</sup>, who reviewed 16 cases of endocarditis due to various species of *Moraxella*, including five cases due to *M. lacunata*. Prior to this Robles et al<sup>4</sup> had reported a case of *M. lacunata* producing prosthetic valve endocarditis. Subsequently, two more cases were reported by Noman F et al<sup>5</sup>, and Kutlesa M et al<sup>6</sup>. Only four of these cases fulfilled the modified Duke's criteria.

Despite its rarity, *Moraxella* endocarditis can be severe. Systemic embolisation can occur to multiple organs including the brain and spleen. *M. lacunata* has a relatively predictable antibiotic profile and is most often sensitive to beta-lactams, although beta-lactamase producing strains have occasionally been reported.<sup>7</sup> In our case, the isolate was not a beta-lactamase producing strain, and could therefore be treated by ceftriaxone and gentamicin.

Our case is unique in many ways. It fulfils the modified Duke's criteria, making it a definite case of *M. lacunata* endocarditis. Unlike the majority of previously reported cases which involved prosthetic valves, our patient had native valve endocarditis. Furthermore, she had demonstrable multivalvular involvement, which has not been previously reported.

This case conclusively demonstrates the pathogenic potential and aggressive course of *M. lacunata*, as illustrated by the involvement of multiple native valves and cerebral embolisation. Awareness of this organism among practising physicians is crucial for institution of early aggressive management and prevention of devastating complications like embolic stroke.

## References

1. Ringvold A, Vik E, Bevanger LS. *Moraxella lacunata* isolated from epidemic conjunctivitis among teen-aged females. *Acta Ophthalmol (Copenh)* 1985;63(4):427-31.

2. Ray U, Kar S. Invasive infection due to *Moraxella lacunata*, an unusual pathogen. *Southeast Asian J Trop Med Public Health* 2006;37(6):1183-6.

3. Maayan H, Cohen Poradosu R, Halperin E, Rudensky B, Schlesinger Y, Yinnon AM, Raveh D. Infective endocarditis due to *Moraxella lacunata*: Report of 4 patients and review of published cases of *Moraxella* endocarditis. *Scand J Infect Dis.* 2004;36(11-12):878-81.

4. Robles M, Tejada J, Jerez V, Pérez D, Jimeno B, Julia JA. Endocarditis caused by *Moraxella lacunata* on the natural and prosthetic valves. An unusual pathogenesis. *Enferm Infecc Microbiol Clin* 1998;16(6):290-1. Spanish

5. Noman F, Khan SG, Khursheed M, Noor SA, Abubaker J. *Moraxella lacunata* endocarditis treated with penicillin. *J Pak Med Assoc* 2008;58:336-7.

6. Kutleša M, Lepur D, Klinar I, Rudež I, Vincelj J, Bukovski S, et al. *Moraxella lacunata*: a rare cause of infective endocarditis. *Scand J Infect Dis* 2007;39(10):917-9.

7. Nagano N, Sato J, Cordevant C, Nagano Y, Taguchi F, Inoue M. Presumed endocarditis caused by BRO beta-lactamase-producing *Moraxella lacunata* in an infant with Fallot's tetrad. *J Clin Microbiol* 2003;41(11):5310-2.

## ACKNOWLEDGEMENTS

Written consent for publication was obtained from the patient.

## PEER REVIEW

Not commissioned. Externally peer reviewed.

## CONFLICTS OF INTEREST

The authors declare that they have no competing interests.

## FUNDING

None.

## CONSENT

The authors declare that:

1. They have obtained informed consent for the publication of the details relating to the patient in this report.
2. All possible steps have been taken to safeguard the identity of the patient.
3. This submission is compliant with the requirements of local research ethics committees.