

## Abdominal scar endometriosis after Caesarean section: a rare entity

Ruchi Sinha<sup>1</sup>, Mohan Kumar<sup>2</sup>, Manjari Matah<sup>3</sup>

1. Senior Resident, Department of Obstetrics and Gynaecology, Institute of Medical Sciences, Banaras Hindu University, Varanasi, Uttar Pradesh, India

2. Professor, Department of Pathology, Institute of Medical Sciences, Banaras Hindu University, Varanasi, Uttar Pradesh, India

3. Professor, Department of Obstetrics and Gynaecology, Institute of Medical Sciences, Banaras Hindu University, Varanasi, Uttar Pradesh, India

### CASE REPORT

Please cite this paper as: Sinha R., Kumar M., Matah M. Abdominal Scar Endometriosis after Cesarean Section: A Rare Entity. AMJ 2011, 4, 1, 60-62.

Doi: <http://doi.org/10.21767/AMJ.2011.486>

#### Corresponding Author:

Dr. Ruchi

7, Saryoonagar, Kamachha, Varanasi-221010

U.P. (INDIA)

[dr.ruchi\\_bh@yaho.com](mailto:dr.ruchi_bh@yaho.com)

### Abstract

Scar endometriosis is an uncommon entity. It is often misdiagnosed leading to unnecessary referrals. Gynaecologists and general surgeons must be aware of this entity to avoid discomfort to the patient due to delay in diagnosis. We are presenting a case of scar endometriosis which was misdiagnosed initially. Detailed history of cyclic pain and swelling was the key point for the final diagnosis of scar endometriosis. Medical therapy was ineffective. Surgical excision of mass was the treatment for endometriotic lesion. This article is an attempt to create awareness of this condition among gynaecologists and general surgeons.

**Key Words:** Endometriosis, scar endometriosis, surgical excision

### Background

Endometriosis occurs in 10% of the female population.<sup>1</sup>The most frequent sites of involvement are the pelvic organs and peritoneum. Scar endometriosis is a rare entity.<sup>2</sup> It occurs following obstetrical and gynaecological surgeries.<sup>2, 3, 4, 5</sup> The condition is often misdiagnosed. The cases are commonly referred to general surgeons as the features mimic surgical cause.<sup>6</sup> The general surgeons and gynaecologists must be aware of this rare condition to avoid delay in diagnosis. We

present a case of scar endometriosis in which lack of awareness of this condition lead to delay in diagnosis.

#### Case Report

A 31 years old Para<sub>1+0</sub> was having pain and swelling of lower abdomen below umbilicus in the midline for last 2 years. She was taking treatment from private practitioner but was not getting any relief; instead the swelling was progressively increasing in size. The patient was referred to the general surgeon for the swelling where the diagnosis of stitch granuloma or lipoma was made. The patient was also referred to our gynaecological outpatient department for the dysmenorrhoea. On taking thorough history, she revealed that there was swelling in the abdominal scar of caesarean section which was performed eight years back increases and become painful during menses. On examination there was a firm tender mass of 4cm × 3cm in the vertical midline scar of her previous caesarean section. The diagnosis of scar endometriosis was made on the clinical ground. The patient was put on danazol 100mg twice daily for 3 month the pain, however the swelling persisted. Finally a surgery was planned after treatment of 3months of danazol. The mass was confined to the subcutaneous tissue (Fig.1).

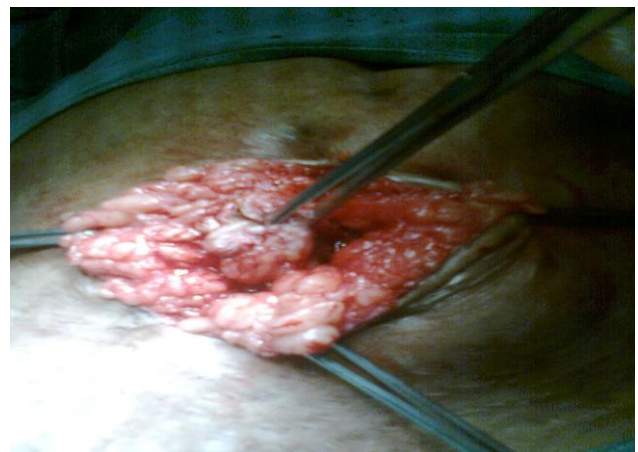

Fig.1 Encapsulated mass surrounded by pale subcutaneous tissue on laparotomy (Endometriotic mass)

The wide excision of mass was done (Fig.2). There was no communication between mass and peritoneal cavity. The post operative period was uneventful. The histopathology of mass confirmed the diagnosis of scar endometriosis (Fig.3). The patient is doing well in follow up.

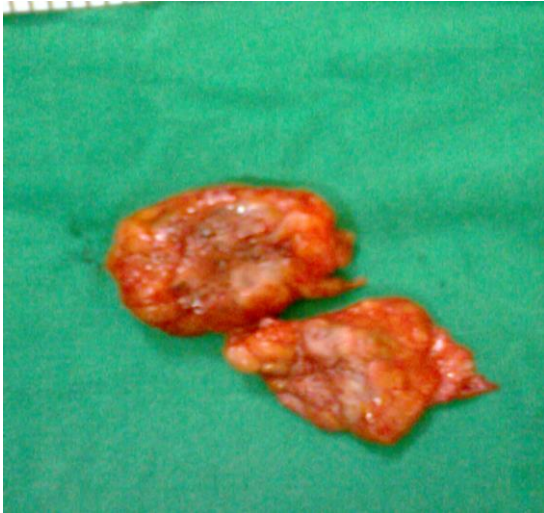

Fig 2: Excised endometriotic tissue

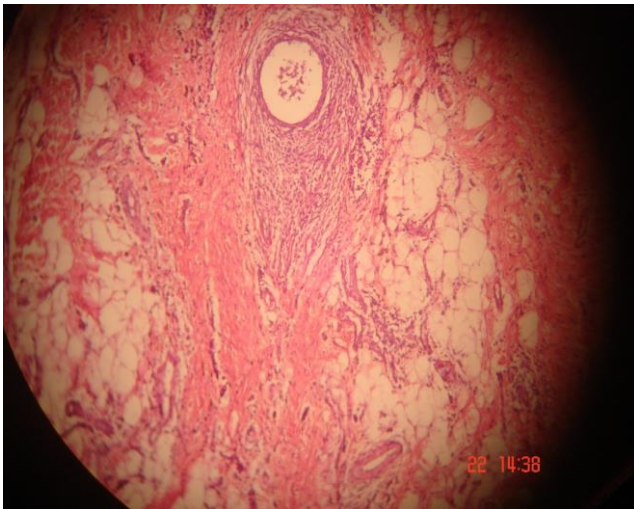


Fig 3: Histopathology showing endometriotic glands in subcutaneous tissue.

### Discussion

Endometriosis is the presence of glandular and stromal tissue in areas outside the uterus. It occurs almost exclusively in women of reproductive age.<sup>1</sup> The sites of involvement, in decreasing order of frequency are, the ovaries, pelvic sub peritoneal spaces, the intestinal system and the urinary system.<sup>7</sup> Extra peritoneal endometriosis is an uncommon finding and the scar endometriosis is a rare entity.<sup>3</sup>

Scar endometriosis usually follows obstetrical and gynaecological surgeries as was in our case but a few cases have been reported following appendectomy, in the laparoscopic trochar tract and amniocentesis needle tract. The incidence of abdominal scar endometriosis following hysterectomy and caesarean section are 1.08-2% and 0.03-0.4% respectively.<sup>3, 4</sup> The cases of endometriosis of uterine wall scar have also been reported in literature but that is an

extremely rare condition.<sup>5</sup> The aetiology of scar endometriosis is believed to be due to the direct inoculation of abdominal fascia or subcutaneous tissue with endometrial cells. This is supported by the experiments in which the normal menstrual effluent transplanted to the abdominal wall resulted in subcutaneous endometriosis.<sup>8</sup> These endometrial cells either proliferate or induce metaplasia in the surround cells under the influence of estrogens to cause endometriosis.<sup>9</sup> As the early decidual cells have more pluripotential capabilities there is higher incidence of abdominal scar endometriosis following hysterectomy. Scar endometriosis usually presents as firm nodular lump at the site of surgical scar accompanied by cyclical pain and swelling during menses. The cyclic nature of signs and symptoms in our patient was the key point for the diagnosis of scar endometriosis. Differential diagnosis includes hernias, lipomas, hematomas, abscesses, cheloids, suture granulomas, sebaceous cysts, malignant tumours including desmoid tumors, sarcomas, lymphomas or primary malignancies of the skin and metastatic tumors.<sup>6</sup> The simultaneous occurrence of pelvic endometriosis with scar endometriosis is infrequent.<sup>10</sup>

The diagnosis is mainly based on clinical grounds as in our case. Other diagnostic modalities include Ultrasound with colour Doppler, CT scan and MRI. On 2-D sonography, scar endometriosis lesion may appear as cystic or multi cystic, mixed or solid masses, with internal vascularity on power Doppler, but these findings are non-specific.<sup>11</sup> CT scan also does not play any specific diagnostic role. MRI is more useful modality for pre-surgical assessment of deep pelvic endometriosis, infiltration of abdominal wall muscles and subcutaneous tissues<sup>9</sup> but MRI is not cost-effective. Fine needle aspiration cytology has been used to assist in establishing the diagnosis. But when suspicion of incision hernia is present, this diagnostic modality should not be used. Also, recent reports have shown that FNAC could not diagnose scar endometriosis in many patients.<sup>12</sup>

The treatment modalities for scar endometriosis are medical and surgical. Medical treatment include combined oral contraceptives, danazol and GnRH analogues, but the response is partial as was in our case and also there is high rate of recurrence after discontinuation of treatment. Wide excision of the lesion is the treatment of choice. In patients whom a large defect remains following excision, mesh can be used for repair.<sup>3</sup> These patients need follow-up as there are chances of recurrence which can be managed successfully with re-excision. For prevention of the occurrence of scar endometriosis it has been suggested that at the end of obstetric and gynaecological surgeries the abdominal wall should be cleaned thoroughly and irrigated vigorously with high jet solution before closure.<sup>13</sup>



## Conclusion

No long duration pain should be taken for granted. A high index of suspicion of scar endometriosis should be there for a surgical scar swelling with cyclical pain. The MRI can be helpful for preoperative assessment. Surgical excision is the treatment of choice. Regular follow-up is necessary to detect recurrence.

## Consent

Written informed consent was taken from the patient for the publication of this case report and any accompanying images.

## CONFLICTS OF INTEREST

The authors declare that they have no conflict of interest.

---

## References

1. Kataoka ML, Togashi K, Yamaoka T, Koyama T, Ueda H, Kobayashi H, et al . Posterior cul-de-sac obliteration associated with endometriosis: MR imaging evaluation. *Radiology* 2005; 234:815-23
2. Balleyguier C, Chapron C, Chopin N, Hélénon O, Menu Y. Abdominal Wall and Surgical Scar Endometriosis: Results of Magnetic Resonance Imaging. *Gynecol Obstet Invest* 2003;55:220-224
3. Goel P, Sood SS, Dalal A, Romilla. Cesarean scar endometriosis: Report of two cases. *Indian J Med Sci* 2005; 59:495-8.
4. Taff L, Jones S. Cesarean scar endometriosis: A report of two cases. *J Reprod Med* 2002; 47:50-2
5. Kafkasli A, Franklin RR, Sauls D. Endometriosis in the uterine wall cesarean section scar. *Gynecol Obstet Invest* 1996; 42:211-3
6. Seydel AS, Sickel JZ, Warner ED, Sax HC: Extrapelvic endometriosis: diagnosis and treatment. *Am J Surg* 1996, 177:239-241
7. Bazot M, Darai E, Hourani R, Thomassin I, Cortez A, Uzan S, et al . Deep pelvic endometriosis: MR imaging for diagnosis and prediction of extension of disease. *Radiology* 2004; 232:379-89
8. Ridley JH, Edwards K. Experimental endometriosis in the human. *Am J Obstet Gynecol* 1958; 76:783-789.
9. Lahiri Ashim K, Sharma Kiran, Busiri Naser. Endometriosis of the uterine cesarean section scar: A case report. *Women's Imaging* 2008; 18:66-68
10. Chatterjee SK. Scar endometriosis: A Clinicopathological study of 17 cases. *Obstet Gynecol* 1980; 56:81-4
11. Wu YC, Tsui KH, Yuan CC, Ng HT: *High-frequency power Doppler angiographic appearance and microvascular flow velocity in recurrent scar endometriosis. Ultrasound Obstet Gynecol* 2003, 21:96-97
12. Dwivedi AJ, Agarwal SN, Silva YJ. Abdominal wall endometriomas. *Dig Dis Sci* 2002; 47:456-61.
13. Wasfie T, Gomez E, Seon S, Zado B. Abdominal wall endometrioma after cesarean section: a preventable complication. *Int Surg* 2002; 87:175-7.

## PEER REVIEW

Not commissioned. Externally peer reviewed.