

## Capsaicin 8% patch in trigeminal neuralgia: Case reports

Maria Luz Cánovas Martinez, Nuria Adan, Andrea Carballude, Laura Lamelas, Eva Villar, and Pilar Seoane

Department of Anesthesiology CHUO, Pain Unit, Ourense, Spain

### CASE STUDY

Please cite this paper as: Cánovas Martinez ML, Adan N, Carballude A, Lamelas L, Villar E, Seoane P. Capsaicin 8% patch in trigeminal neuralgia: Case reports. AMJ 2019;12(3):98–102.

<https://doi.org/10.21767/AMJ.2018.3573>

#### Corresponding Author:

Maria Luz Cánovas Martinez

Department of Anesthesiology CHUO, Pain Unit,  
Ourense, Spain

Email: [maria.de.la.luz.canovas.martinez@sergas.es](mailto:maria.de.la.luz.canovas.martinez@sergas.es)

### ABSTRACT

Capsaicin 8% patch has a verified analgesic effect in post herpetic neuralgia, diabetic neuropathy, surgical neuropathy and other cases of peripheral neuropathic pain.

We report two cases of trigeminal neuralgia, idiopathic and post-herpetic, with cold and pinprick hyperalgesia and with poor response to antiepileptic drugs and sympathetic blockade of the stellate ganglion, treated with capsaicin 8% patch for 60 minutes covering the area of pain.

In both cases observed: Repeated treatments have had similar efficacy, significant reduction in the pain area and reduction of the concomitant medication.

Cold and pinprick hyperalgesia may be correlated with effective response to capsaicin 8% patch as in other studies.

#### Key Words

Trigeminal neuralgia, capsaicin patch, allodynia, hyperalgesia

### Implications for Practice:

#### 1. What is known about this subject?

Trigeminal neuralgia (TN) is one of the most excruciating pain conditions. Epidemiological studies reveal a global incidence of approximately 4–28.9 per 100,000 individuals. However, up to 10 per cent of patients with this condition do not respond to antiepileptic drugs.

#### 2. What new information is offered in this case study?

Presence of cold and pinprick hyperalgesia may be correlated with effective response to the capsaicin 8% patch in patients with trigeminal neuralgia with poor response to antiepileptic drugs.

#### 3. What are the implications for research, policy, or practice?

The early initiation of topical treatment might be indicated in patients with trigeminal neuralgia with this symptomatology as the second line of treatment.

### Background

The capsaicin 8% (QUTENZA®) is an adhesive patch containing a high concentration (8 per cent) of synthetic capsaicin, a selective agonist of the transient receptor potential vanilloid 1 channel. In normal skin without spontaneously active nociceptors, capsaicin administration will induce activation of nociceptors. However, the parallel process of defunctionalisation is also initiated, and if the capsaicin exposure is sufficient, the nociceptors will cease to function, resulting in decreased afferent barrage and pain. This oversimplification ignores the cutaneous concentration gradient and the activation without defunctionalisation that may occur in the dermis.

A systematic review and meta-analysis published by Finnerup et al.<sup>1</sup> recommends capsaicin 8% as second line treatment for peripheral neuropathic pain. Capsaicin has a verified analgesic effect in post herpetic neuralgia,<sup>2</sup> diabetic neuropathy,<sup>3</sup> surgical neuropathy and other cases of peripheral neuropathic pain.<sup>4</sup>

Trigeminal nerve is the fifth cranial nerve and is responsible for general head and face sensitivity. Trigeminal neuralgia (TN) is one of the most common neuropathic pains found in the head and neck. It is manifested as shock or burning crises in undefined intervals, and is typically triggered by non-painful stimulation in the face (allodynia). Different mechanisms are involved in the onset and maintenance of neuropathic pain both at peripheral and central levels.<sup>5</sup>

Trigeminal neuralgia is initially managed pharmacologically. The selection of an interventional treatment is preceded by an accurate diagnosis with attention to vascular compression and potential neuropathy. Radiofrequency thermocoagulation of the Gasserian ganglion is well-documented and is the preferred percutaneous treatment. There is evidence that efficacy and safety are improved when the electrode placement is more precisely controlled, as with the neuronavigation techniques. The effect of pulsed radiofrequency treatment is shorter, but this treatment may be considered for patients at risk. When vascular compression is an important factor, microvascular decompression is preferred. On the other hand, neuromodulation may be indicated in cases of intractable neuropathy.<sup>6</sup>

We report two cases of trigeminal neuralgia, idiopathic and post-herpetic, treated with capsaicin 8% patch.

## Case Details

### Case 1

A 44-year-old woman, without personal history of interest consulted our pain unit because of pain in the left facial area with lancinating paroxysms and a burning-like component in the area of the three branches of the trigeminal nerve, which had affected her for two years. The patient reported intense allodynia, hyperalgesia to cold and wind (VAS 9) that prevented her leaving home. Examination revealed pinprick hyperalgesia. She was being treated by another pain unit with carbamazepine 600mg/day, amitriptyline 50mg/day, baclofen (30mg/day) and delayed onset tramadol (150mg/day).

Magnetic resonance: no abnormalities of note. Significant vascular compression of the Gasserian ganglion, association with demyelinating disease and diagnosis of secondary neuralgia were all ruled out.

The patient had been treated with sympathetic blockade of the stellate ganglion without efficacy and preferred another therapeutic alternative to the radiofrequency of the Gasserian ganglion.

The doctors and patient decided to place a capsaicin 8% patch for 60 minutes covering the area of pain and to protect the eye with eye dressing and cream.

At the onset of treatment, she presented severe burning sensation (VAS 8) that reduced to moderate (VAS 4) upon withdrawal and moderate erythema (5 on a scale of 0 to 10). When the patch was withdrawn, the patient reported a reduction in allodynia from 9 to 6.

One month after treatment the patient reported reduction of the area of pain by 20 per cent, reduction of the number of episodes of lancinating paroxysms and pain-free days that enabled a reduction in medication as follows: carbamazepine (400mg/24h), amitriptyline (25mg/24h) and baclofen (20mg/24h). The improvement lasted for 16 weeks.

New treatment with capsaicin 8% patch was decided for the patient's residual neuralgia; the affected area was covered, and eye protection was worn. After this second application the erythema was more intense than the first time and the initial burning sensation was severe (VAS 9) and came down (VAS 6) after withdrawal of the patch. Pain intensity reported was VAS 3, and duration of the analgesic effect was 24 weeks. The reduction of the pain area was >75 per cent on the affected side. In this review the patient reported new pain symptoms, considered as trigeminal "mirror-image" neuralgia that includes the second and third branch on the contralateral side. Figure 1 shows a gradual reduction of the pain area with successive applications; Figure 2 shows the "mirror-image" pain area.

The patient once again had to increase carbamazepine (600mg) to control contralateral pain. Placement for 60 minutes of the capsaicin 8% patch on the left side was prescribed in a very reduced area as shown by Figure 1 and on the right side covering the pain area as shown by Figure 2. One month from treatment the patient reported a reduction in pain in both areas treated (VAS 2).

### Case 2

A 63-year-old man visited the pain unit because of pain in the left facial area in the area of the first branch of the trigeminal nerve in relation to ophthalmic herpes zoster (HZ) with clinical course of less than one month. The patient no longer presented lesions in the corresponding area but reported onset of severe, burning pain for more than six days with a lancinating component, VAS 10, which had been increasing since onset. The patient was diagnosed with acute HZ in the first branch of the left trigeminal nerve.

It was decided to commence treatment with amitriptyline 25mg (half a tablet at night increased at three days treatment to 1 tablet/24 hours), gabapentin 300mg/24h with weekly increases of 1 tablet up to 900mg/day and delayed tramadol 400mg/24h.

Two months after starting treatment the patient came for review and continued to report continuous pain in the area of the first branch of the left trigeminal nerve, VAS 7, with a significant burning sensation. The lancinating aspect disappeared, but the patient reported presentation of severe allodynia and pinprick hyperalgesia as intensity 9 (VAS). A sympathetic blockade of the stellate ganglion was prescribed but was not effective. He was offered treatment with Capsaicin, and the patient accepted.

Capsaicin 8% patch was applied for 60 minutes in the area of pain with ocular protection in both eyes and eyelids with wet gauze and occlusive patch. Erythema and burning after the procedure were minimal and temporary. One week from treatment we observed a reduction of the pain area; minimal allodynia remained on the left ciliary region (VAS1).

A new patch was applied three months after the first because of increased pain (VAS 5) and allodynia (VAS 3). One week from the placement a significant reduction in pain intensity and allodynia was again observed (VAS 1).

Six months after the second treatment, the patient reported mild discomfort (VAS 1) free of allodynia while receiving amitriptyline treatment 10mg/24h. Treatment was discontinued due to the patient's lack of pain.

Figure 3 shows the reduction of the pain area after initial application.

## Discussion

There is very low quality evidence for the efficacy of most neurosurgical procedures for trigeminal neuralgia because of the poor quality of the trials. All procedures produce variable pain relief, but many result in sensory side effects. There have been no studies of microvascular decompression which observational data suggests gives the longest pain relief. There is little evidence to help comparative decision making about the best surgical procedure<sup>7</sup>. Sympathetic nerve block has beneficial effects in patients with acute HZ but does not appear to provide long-term pain relief in PHN patients<sup>8</sup>. Patient 1 had a normal magnetic resonance. The performance of a vascular decompression was not justified. Both patients preferred

another therapeutic alternative to the radiofrequency thermocoagulation of the Gasserian ganglion.

Capsaicin 8% patch has been successfully used for treatment of symptoms of peripheral neuropathic pain either alone or in association with other analgesics.<sup>9</sup>

The existence of cold and pinprick hyperalgesia correlates with the response to the patch<sup>10,11</sup> as occurs in the two case studies reported.

Repeated treatments have had similar efficacy in our patients, which coincides with results from other studies<sup>2</sup>.

Efficacy was greater in patient 2, in which the patch was applied two months from the onset of pain symptoms. Maihofner et al.<sup>12</sup> published greater efficacy of capsaicin 8% patch in those patients with less clinical course, when treatment commenced before six months from onset of pain.

In both cases concomitant medication (antidepressants, anticonvulsants and opioids) could be reduced; part of the medication could even be discontinued in the latter case. Wagner et al.<sup>13</sup> In a retrospective analysis, patients treated with capsaicin found that more than 50 per cent can discontinue oral treatment.

The significant reduction in the pain area in both cases, observed after initial application, coincides with that published by other studies.<sup>14</sup>

Trigeminal neuralgia is one of the most common causes of orofacial pain. It is defined clinically by the presence of paroxysmal, stereotypical attacks of usually intense, sharp, superficial or stabbing pain in the distribution of one or more branches of the trigeminal nerve. Bilateral and especially simultaneous bilateral symptoms should arouse suspicion of a systemic cause.<sup>15</sup> Patient 1 turned out to be an atypical case of trigeminal neuralgia, of idiopathic aetiology, because it was unrelated to any systemic process or radiological abnormality. Both cases effectively responded to treatment with capsaicin 8% patch. Capsaicin, as a cream, was an effective treatment for trigeminal neuralgia in combination with other drugs<sup>16</sup>. The reduction of the area of pain and the longer duration of the analgesia with the successive applications allow us to consider the capsaicin 8% patch a second line of treatment for this pain with an incidence of minimal, temporary effects related to application.

## Conclusion

These findings suggest that in those patients with trigeminal neuralgia experiencing cold and pinprick hyperalgesia, the early initiation of topical treatment might be indicated. The limitations of this study are based on the lack of comparison of the effectiveness of the patch with other patients with this same diagnosis but without hyperalgesia. The findings warrant further investigation with a larger number of patients in prospective trials.

---

## References

1. Finnerup NB, Attal N, Haroutounian S, et al. Pharmacotherapy for neuropathic pain in adults: a systematic review and meta-analysis. *Lancet Neurol.* 2015;14:162–173.
2. Backonja MM, Backonja MM, Malan TP, et al. NGX-4010, a high-concentration capsaicin patch, for the treatment of postherpetic neuralgia: a randomized, double-blind, controlled study with an open-label extension. *Pain Med.* 2010;11:600–608.
3. Simpson DM, Robinson-Papp J, Van J, et al. Capsaicin 8% Patch in painful diabetic peripheral neuropathy: a randomized, double-blind placebo-controlled study. *J Pain.* 2016;18:42–54.
4. Haanpää M, Cruccu G, Nurmikko TJ, et al. Capsaicin 8% patch versus oral pregabalin in patients with peripheral neuropathic pain. *Eur J Pain.* 2016;20:316–328.
5. Ferreira G, De Almeida C. Trigeminal neuralgia: peripheral and central mechanisms. *Rev Dor.* 2015;16:297–301.
6. Van Buyten JP. Interventional treatment for trigeminal neuralgia: Radiofrequency and neuromodulation. In: N. Narouze S. (eds) *Interventional Management of Head and Face Pain.* Springer, New York, NY. 2014.
7. Zakrzewska JM, Akram H. Neurosurgical interventions for the treatment of classical trigeminal neuralgia. *Cochrane Database Syst Rev.* 2011;9:CD007312. doi:10.1002/14651858.CD007312.pub2.
8. Jeon YH. Herpes zoster and postherpetic neuralgia: practical consideration for prevention and treatment. *Korean J Pain.* 2015;28:177–84.
9. Burness CB, McCormack PL. Capsaicin 8 % Patch: A review in peripheral neuropathic pain. *Drugs.* 2016;76:123–134.
10. Mainka T, Malewicz NM, Baron R, et al. Presence of hyperalgesia predicts analgesic efficacy of topically applied capsaicin 8% in patients with peripheral neuropathic pain. *Eur J Pain.* 2016;20:116–129.
11. Gustorff B, Poole C, Kloimstein H, et al. Treatment of neuropathic pain with the capsaicin 8% patch: Quantitative sensory testing (QST) in a prospective observational study identifies potential predictors of response to capsaicin 8% patch treatment. *Scand J Pain.* 2013;4:138–145.
12. Maihofner C, Heskamp ML. Treatment of peripheral neuropathic pain by topical capsaicin. Impact of pre-existing pain in the QUEEP- Study. *Eur J Pain.* 2014;18:671–679.
13. Wagner T, Poole C, Roth-Daniek A. The capsaicin 8% patch for neuropathic pain in clinical practice: a retrospective analysis. *Pain Med.* 2013;14:1202–1211.
14. Zis P, Apsokardos A, Isaia C, et al. Posttraumatic and postsurgical neuropathic pain responsive to treatment with capsaicin 8% topical patch. *Pain Physician.* 2014;17:E213–E218.
15. Vivek J, Rahul A, Neil G. Granulomatosis with polyangiitis masquerading as bilateral trigeminal neuralgia. *J Med Cases.* 2016;7:384–385.
16. Ali M, Haider SM. Analgesic effects of topical 0.075% capsaicin with oral carbamezipine in idiopathic trigeminal neuralgia. *Int J Oral Maxillofac Surg.* 2007;36:1027.

## PEER REVIEW

Not commissioned. Externally peer reviewed.

## CONFLICTS OF INTEREST

The authors declare that they have no competing interests.

## FUNDING

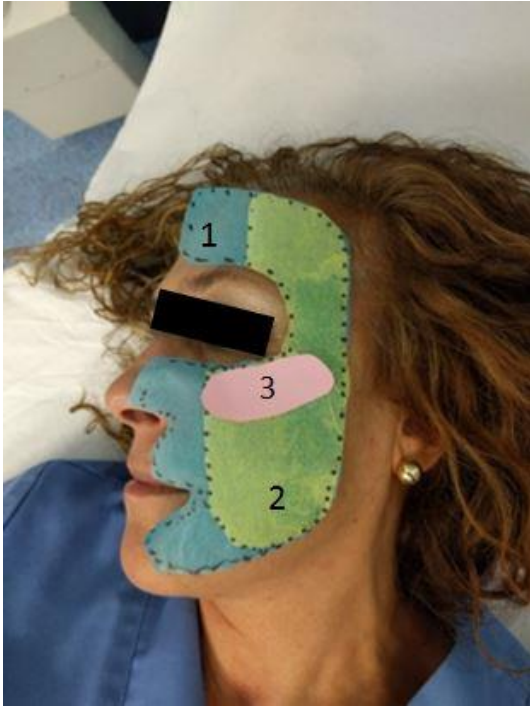
None

## PATIENT CONSENT

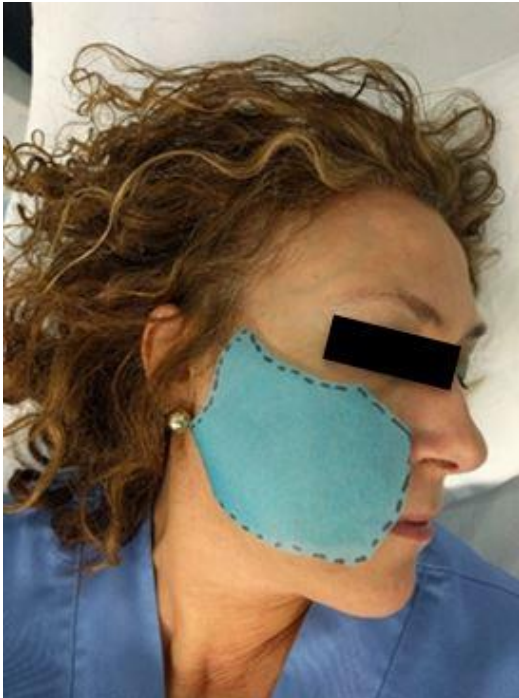The authors, *Cánovas L, Adán N, Carballude A, Lamelas L, Villar E, and Seoane P*, declare that:

1. They have obtained written, informed consent for the publication of the details relating to the patient(s) in this report.
2. All possible steps have been taken to safeguard the identity of the patient(s).
3. This submission is compliant with the requirements of local research ethics committees.

**Figure 1: Areas of pain after successive applications (1. Basal; 2. 1<sup>st</sup> application; 3. 2<sup>nd</sup> application)**



**Figure 2: Area of pain on the contralateral side**



**Figure 3: Reduction of the pain area (1) after initial application of capsaicin 8% patch (2)**

