

Fluconazole-Warfarin interaction: A case report with deadly consequences

Elliot V Hersh¹, Mana Saraghi², Jamie Lowstetter³, Paul A Moore⁴, and Anita Aminoshariae⁵

1. Department of Oral & Maxillofacial Surgery and Pharmacology, University of Pennsylvania School of Dental Medicine, Philadelphia PA, USA

2. Dental Anesthesiology, Jacobi Medical Center, Department of Dentistry/Oral and Maxillofacial Surgery, Bronx, NY, USA

3. University of Pennsylvania School of Dental Medicine, Philadelphia PA, USA

4. Dental Anesthesiology and Dental Public Health, Department of Dental Public Health, School of Dental Medicine, University of Pittsburgh, Pittsburgh PA, USA

5. Department of Endodontics, Case Western Reserve University, School of Dental Medicine, Cleveland, Ohio, USA

CASE STUDY

Please cite this paper as: Hersh EV, Saraghi M, Lowstetter J, Moore PA, Aminoshariae A. Fluconazole-Warfarin interaction: A case report with deadly consequences. AMJ 2017;10(6):544–549.

<https://doi.org/10.21767/AMJ.2017.3049>

Corresponding Author:

Elliot V Hersh

University of Pennsylvania School of Dental Medicine
Department of Oral Surgery and Pharmacology
240 South 40th Street, Philadelphia, PA 19104-6030, USA
Email: evhersh@upenn.edu

ABSTRACT

Adverse drug-drug interactions are more common in the elderly because of the commonality of polypharmacy. When one of the interacting drugs has a low therapeutic index, the consequences can be life-threatening or fatal. This case describes a fatal cerebral haemorrhage in an 80-year old male on stable doses of warfarin prescribed by his cardiologist, who was prescribed fluconazole 200mg, once daily, for 14 days by an oral and maxillofacial surgeon to treat an intraoral fungal infection. The oral surgeon was aware that the patient was on warfarin and his INR two days prior to the appointment was 2.4. While a drug interaction alert was sent to the patient's primary care family physician regarding fluconazole and the simvastatin she had been prescribing, the interaction was not reviewed by her for another 9- days. She then informed the patient that "it was fine" to finish the fluconazole. However, this phone

conversation prompted the patient to discontinue the fluconazole after 8 doses. Two days later, the patient was confused and driving his car erratically. His son rushed him to the hospital where a CAT scan revealed a large frontal intraparenchymal haemorrhage. His INR was a 9.6. This event illustrates that this well-documented adverse drug interaction needs to be better highlighted in dental and medical training. Warfarin's primary metabolic pathway involves the cytochrome P-450 2C9 isoform and fluconazole is a strong inhibitor of this enzyme, with the potential outcome being excessive warfarin blood levels. Frequent INR monitoring with potential warfarin dosage adjustments downward if fluconazole is prescribed, or the complete avoidance of fluconazole is recommended in patients taking warfarin. The importance of communication and coordinated care between different health care providers cannot be overstated.

Key Words

Warfarin, fluconazole, adverse drug interactions

Implications for Practice:

1. What is known about this subject?

The ability of fluconazole to inhibit warfarin's metabolism is a serious well-documented adverse drug interaction that may be unknown or underappreciated by many medical specialties.

2. What new information is offered in this case study?

This drug interaction led to a significant increase in the patient's INR and an eventually fatal haemorrhagic stroke.

3. What are the implications for research, policy, or practice?

Clinicians must be aware of drugs with low therapeutic

indices that are metabolized by the cytochrome P-450 system and other pharmaceuticals likely to impede this process.

Background

Warfarin is a drug that is commonly prescribed to prevent thrombi formation, mitigating the enhanced potential of occlusive stroke or pulmonary embolism in patients with atrial fibrillation, deep venous thrombosis and other hyperthrombotic disorders.^{1,2} It is a vitamin K antagonist that interferes with the hepatic synthesis of the procoagulant vitamin K dependent clotting factors II, VII, IX and X, as well as the synthesis of the anticoagulant proteins C, S and Z.³ It is primarily metabolized by cytochrome P-450C9 (CYP2C9).⁴ Warfarin has a low therapeutic index, meaning the difference between therapeutic and toxic blood levels is relatively small, making it uniquely poised to be involved in serious adverse drug interactions.⁵

Fluconazole is an antifungal agent which is effective in the treatment of mucosal candidiasis, including candida infections in the oral cavity.⁶ In addition, compared to otherazole antifungal drugs, it has the best penetration into the central nervous system, making it especially useful against infections like Cryptococcal meningitis.⁷ While the drug is routinely used on an inpatient and outpatient basis, there is an underappreciation for the potentially severe and life-threatening drug interactions with which fluconazole can be associated.⁵

Fluconazole is a potent inhibitor of CYP2C9 both prehepatically and in the liver.^{8,9} The clinical implications of this property is that fluconazole can inhibit the metabolism of and cause the accumulation of CYP2C9 substrates, including warfarin.^{5,10} Table 1 illustrates some inhibitors of CYP2C9.^{4,11} Several studies have reported significantly elevated prothrombin times (PTs) and INRs with the simultaneous intake of both drugs.¹²⁻¹⁴ More alarming, unexpected bleeding including GI, intraocular and epidural has also been reported with this combination.¹⁵⁻¹⁸ In one case the patient had been diagnosed with a fungal infection of the GI tract, placed on fluconazole and his INR rose from 2.2 to 40.¹⁸

The following case describes a fatality in an 80-year-old male on stable warfarin doses for atrial fibrillation who was prescribed fluconazole for an intraoral fungal infection.

Case details

This case is of an 80-year-old male (BMI 31.6) with atrial fibrillation, hypercholesteremia and angina who was

referred to an oral surgeon because of lower premolar tooth pain, and hyperplastic tissue in the right maxillary first and second molar region which was not allowing his partial denture to seat. The patient's medication intake was warfarin 5mg once daily (OD) for atrial fibrillation, simvastatin 20mg OD and gemfibrozil 600mg BID for hypercholesteremia, isorbide mononitrate 60mg OD and sublingual nitroglycerin PRN for angina, acetylsalicylic acid 81mg per day for cardioprotection, meclizine 25mg OD for vertigo and lorazepam (unknown dose) prn for anxiety. In the previous 3 years, his international normalized ratio (INR) had remained between 2.2 and 2.6. While a cardiologist was managing the patient's warfarin intake by ordering monthly INRs, a board-certified family care physician was handling all other medication intake. His vital signs were: blood pressure 160/120 and pulse: 76. (Temperature and respiration rate were not taken) The oral surgeon and his surgical assistant were presented with a complete medication list by the patient. Two days prior to this oral surgery appointment, the patient's INR was 2.4 and the oral surgeon had specifically requested this information from the patient's cardiologist.

On further examination of the patient's oral soft tissues, the oral surgeon noted hyphae like structures and redness on the palatal mucosa under his maxillary partial denture. The lower premolar tooth was extracted uneventfully and a small amount hyperplastic tissue in the maxillary molar region was removed under local anesthesia with 3.6ml of 2 per cent lidocaine (72mg) plus 1:100,000 epinephrine (0.036mg), and 1.8ml of 3 per cent mepivacaine (54mg). The oral surgeon prescribed acetaminophen 300mg plus codeine 30mg prn for postoperative pain control and fluconazole 200mg OD for 14 days for what appeared to be a generalized *Candida albicans* infection (papillary hyperplasia) on the palatal tissue beneath the denture. The patient was advised not to wear the denture until his condition was re-evaluated in two weeks.

The patient had the fluconazole prescription filled by a "chain pharmacy" who was not currently filling his warfarin and other chronic-intake prescriptions. A mail order pharmacy was filling these prescriptions. However, the chain pharmacy had filled his warfarin prescriptions as recently as two years prior to the current fluconazole prescription.

On the day that the fluconazole prescription was filled, the mail order pharmacy sent out a drug interaction alert to the patient's primary care family physician with regards to fluconazole and simvastatin. The primary care physician did

not review this computer-generated report until day 9 of the patient's fluconazole intake. On reviewing the report, the physician's office assistant called the patient and informed the patient's wife about this possible interaction but did not describe what the possibilities of the drug-drug interaction could be. The patient's wife asked if the family care physician could directly call her or her husband about this alert. The physician promptly returned the call. She informed the patient and his wife that "since nothing adverse had happened so far, plus the fact he was nearing the end of his prescription course, he could finish his fluconazole prescription". However, the patient did not want "to take any chances with all the medication he was on" and discontinued the fluconazole on his own. He had dosed with fluconazole for 9 days.

One day after the patient's discontinuation of fluconazole, his cardiologist received a drug interaction alert with regards to fluconazole and warfarin. Two days later at a family gathering in a restaurant, the patient was "not acting himself". He appeared a little confused and was not conversing as vibrantly as he usually did. The patient and his wife felt like he might be coming down with something and decided to drive home with the patient at the wheel. On driving home, the patient was not holding the road well and was driving down incorrect streets. His wife took over the wheel, called the patient's son who lived next door and told him she thought that his father was having a stroke.

The son immediately drove his father and mother-in-law to the hospital. Upon arrival, the patient was semi-conscious (Glasgow coma score=11) and not adequately responding to verbal queries by the emergency department physician. A CAT scan of the brain was ordered and it revealed a significant right frontal lobe bleed. An INR was then immediately ordered and the patient's INR was 9.6. Intramuscular Vitamin K 10mg (the antidote for a warfarin overdose) was administered, along with 6 units of fresh frozen plasma and 6 units of platelets. After his blood coagulation levels stabilized, he was taken to the operating room for an emergency craniotomy.

The patient remained in the hospital for 4 months. During the initial 3-months the patient's condition seemed to be improving with the ability to ambulate with assistance and occasional short conversations with his family and attending hospital staff. However, his condition subsequently deteriorated. He became semiconscious, then unconscious despite aggressive therapy. He passed away in the hospital.

Discussion

The fluconazole-warfarin adverse drug interaction has been well-described in the literature based on both pharmacokinetic studies and case reports with the potential outcome being serious bleeding.^{4,5,8-18} Warfarin is actually a racemic compound with the S-isomer being the more potent isomer with regards to the drug's anti-coagulant activity.¹⁹ Its primary metabolic pathway is via CYP2C9 (Figure 1) and strong inhibitors of this enzyme such as fluconazole and metronidazole can inhibit warfarin's metabolism and lead to excessive blood levels of the drug and correspondingly supra-therapeutic INRs.^{4,5,8-10,20,21} In a retrospective study of 22,272 United States Veterans between 2002 and 2008 on stable doses of warfarin for at least 30 days that were exposed to antibiotics thought to interact adversely with warfarin, 2.3 per cent of them who received fluconazole had major bleeding events, with 9.7 per cent having INRs recorded above the level of 6.0.²² The significantly elevated and untreated blood pressure exhibited by this patient (recorded as 160/120 when his vitals were taken by the oral surgeon) may have further added to the drug interaction's severity. The combination of antiplatelet therapy (acetylsalicylic acid 81 mg), anticoagulant therapy (warfarin) and hypertension in the absence of elevated warfarin levels, is known to increase the risk of haemorrhagic stroke.^{23,24} To our knowledge this is the first reported case where the administration of fluconazole to a patient on stable warfarin doses, was the major contributing factor to the haemorrhagic stroke that ultimately led to the demise of this individual.

The initial drug interaction alert involving fluconazole and simvastatin revolved around the primary metabolic pathway of simvastatin being cytochrome P-450 3A4 (CYP3A4).⁴ Fluconazole is a moderate inhibitor of CYP3A4 with the ultimate effect of the interaction being excessive simvastatin blood levels.^{25,26} Like grapefruit juice, the ability of fluconazole to raise simvastatin blood levels can lead to an increased risk of myalgia and occasionally rhabdomyolysis.^{26,27}

There are several clinically significant "take home messages" from this report.

- The ability of fluconazole to significantly increase warfarin blood levels is underappreciated and must be highlighted in dental and medical training.
- While we as clinicians are often overwhelmed by drug interaction alerts from pharmacies, it behooves us to consider the clinical significance of these possible events. "Alarm fatigue," a desensitization and hypovigilance to multiple alerts, may worsen the problem

as many software systems produce alerts of similar magnitude regardless of the clinical significance of a potential drug-drug interaction.²⁸ The providers are ultimately responsible to discern the potential clinical severity of an interaction.

- This case underscores the importance of interdisciplinary communication between various healthcare providers, especially when prescribing different drugs to the same patient. In this specific case, the oral surgeon never discussed his fluconazole prescription with the cardiologist. The family care physician reviewed the drug interaction alerts “too late in the game” and never contacted the pharmacy about the significance of the first interaction alert between fluconazole and simvastatin.
- Pharmacies can be overburdened by the number of prescriptions they fill and often do not have adequate time to look up prescriptions they filled in the past (in this case warfarin); and ultimately counsel the patient about potential adverse drug interactions with the newly prescribed drug (in this case fluconazole).
- It is likely that this event could have been prevented if the patient’s INR was monitored for any deviations from the therapeutic window during the intake of fluconazole. Warfarin could have been discontinued and/or vitamin K administered.

Conclusion

This paper presents a significant and ultimately lethal drug interaction between fluconazole and warfarin. Warfarin is a drug with a low therapeutic index that is taken by numerous patients with atrial fibrillation and other thrombotic disorders. It is the responsibility for all clinicians to discern if drugs they are prescribing can enhance the ability of warfarin to induce serious bleeding episodes.

References

1. Nutescu EA, Burnett A, Fanikos J, et al. Pharmacology of anticoagulants used in the treatment of venous thromboembolism. *J Thromb Thrombolysis*. 2016;41(1):15.
2. Stoudenmire LG, DeRemer CE, Elewa H. Telephone versus office-based management of warfarin: impact on international normalized ratios and outcomes. *Int J Hematol*. 2014;100(2):119.
3. Ageno W, Gallus AS, Wittkowsky A, et al. Oral anticoagulant therapy. Antithrombotic therapy and prevention of thrombosis, 9th Edition. American college of chest physicians evidence-based clinical practice guidelines. *Chest*. 2012;141(suppl 2):e44s.
4. Hersh EV, Moore PA. Drug interactions in dentistry: the importance of knowing your CYPs. *J Am Dent Assoc*. 2004;135(3):298.
5. Hersh EV, Moore PA. Three serious drug interactions that every dentist should know about. *Compend Contin Educ Dent*. 2015;36(6):408.
6. Barchiesi F, Giacometti A, Arzeni D, et al. Fluconazole and ketoconazole in the treatment of oral and esophageal candidiasis in AIDS patients. *J Chemother*. 1992;4(6):381.
7. Black KE, Baden LR. Fungal infections of the CNS: treatment strategies for the immunocompromised patient. *CNS Drugs*. 2007;21(4):293.
8. Kunze KL, Wienkers LC, Thummel KE, et al. Warfarin-fluconazole. I. Inhibition of the human cytochrome P450-dependent metabolism of warfarin by fluconazole: in vitro studies. *Drug Metab Dispos*. 1996;24(4):414.
9. Black DJ, Kunze KL, Wienkers LC, et al. Warfarin-fluconazole. II. A metabolically based drug interaction: in vivo studies. 1996;24(4):422.
10. Kaminsky LS, Zhang ZY. Human P450 metabolism of warfarin. *Pharmacol Ther*. 1997;73(1):67.
11. Michalets EL. Update: clinically significant cytochrome P-450 interactions. *Pharmacotherapy*. 1998;18(1):84.
12. Yamamoto H, Habu Y, Yano I, et al. Comparison of the effects ofazole antifungal agents on the anticoagulant activity of warfarin. *Biol Pharm Bull*. 2014;37(12):1990.
13. Turrentine MA. Single-dose fluconazole for vulvovaginal candidiasis: impact on prothrombin time in women taking warfarin. *Obstet Gynecol*. 2006;107(2 Pt 1):310.
14. Crussell-Porter LL, Rindone JP, Ford MA, et al. Low-dose fluconazole therapy potentiates the hypoprothrombinemic response of warfarin sodium. *Arch Intern Med*. 1993;153(1):102.
15. Seaton TL, Celum CL, Black DJ. Possible potentiation of warfarin by fluconazole. *DICP*. 1990;24(12):1177.
16. Kerr HD. Case report: potentiation of warfarin by fluconazole. *Am J Med Sci*. 1993;305(3):164.
17. Mootha VV, Schluter ML, Das A. Intraocular hemorrhages due to warfarin fluconazole drug interaction in a patient with presumed *Candida* endophthalmitis. *Arch Ophthalmol*. 2002;120(1):94.
18. Allison EJ Jr, McKinney TJ, Langenberg JN. Spinal epidural haematoma as a result of warfarin/fluconazole drug interaction. *Eur J Emerg Med*. 2002;9(2):175.
19. Flora DR, Rettie AE, Brundage RC, et al. CYP2C9 Genotype-Dependent Warfarin Pharmacokinetics: Impact of CYP2C9 Genotype on R- and S-Warfarin and Their Oxidative Metabolites. *J Clin Pharmacol*. 2017;57(3):382.
20. Venkatakrisnan K, von Moltke LL, Greenblatt DJ. Effects of the antifungal agents on oxidative drug metabolism:

- Clinical relevance. Clin Pharmacokinet. 2000;38:111.
21. Limdi NA, Veenstra DL. Warfarin pharmacogenetics. Pharmacotherapy. 2008;28(9):1084.
 22. Lane MA, Zeringue A, McDonald JR. Serious bleeding events due to warfarin and antibiotic co-prescription in a cohort of veterans. Am J Med. 2014;127(7):657.
 23. Kai H, Kohro T, Fukuda K, et al. Impact of systolic blood pressure on hemorrhagic stroke in patients with coronary artery disease during anti-platelet therapy: The Japanese Coronary Artery Disease (JCAD) study. Int J Cardiol. 2016;224:112.
 24. Arima H, Anderson C, Omae T, et al. Effects of blood pressure lowering on intracranial and extracranial bleeding in patients on antithrombotic therapy: the PROGRESS trial. Stroke. 2012;43(6):1675.
 25. Molden E, Skovlund E, Braathen P. Risk management of simvastatin or atorvastatin interactions with CYP3A4 inhibitors. Drug Saf. 2008;31(7):587.
 26. Shaukat A, Benekli M, Vladutiu GD, et al. Simvastatin-fluconazole causing rhabdomyolysis. Ann Pharmacother. 2003;37(7-8):1032.
 27. Lee JW, Morris JK, Wald NJ. Grapefruit juice and statins. Am J Med. 2016;129(1):26.
 28. Slight SP, Seger DL, Nanji KC, et al. Are we heeding the warning signs? Examining providers' overrides of computerized drug-drug interaction alerts in primary care. PLoS One. 2013;8(12):e85071.

PEER REVIEW

Not commissioned. Externally peer reviewed.

CONFLICTS OF INTEREST

The authors declare that they have no competing interests.

FUNDING

None

PATIENT CONSENT

The authors, *Hersh EV, Saraghi M, Lowstetter J, Moore PA, Aminoshariae A*, declare that:

1. They have obtained written, informed consent for the publication of the details relating to the patient(s) in this report. N/A
2. All possible steps have been taken to safeguard the identity of the patient(s). Hersh EV, Saraghi M, Lowstetter J, Moore PA, Aminoshariae A
3. This submission is compliant with the requirements of local research ethics committees. N/A

Figure 1: Metabolic disposition of S- and R- warfarin. S- Warfarin is the most potent isomer and is metabolized by a single CYP enzyme²¹

Warfarin: Pharmacokinetic & Pharmacodynamic Pathways

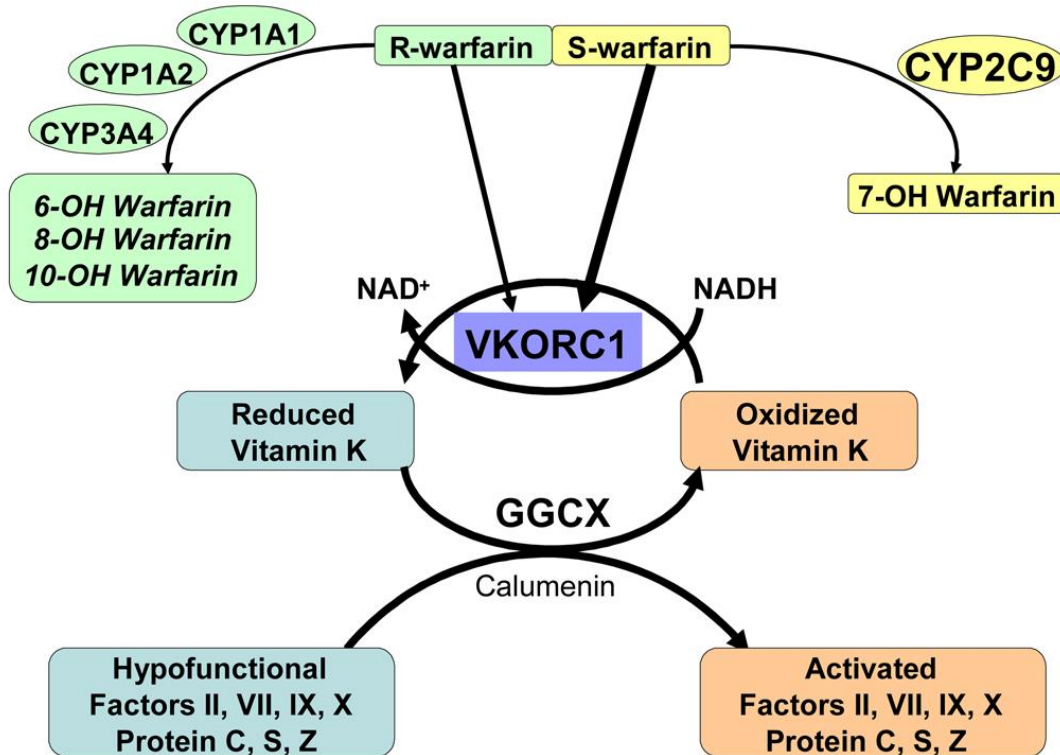


Table 1: Some CYP2C9 inhibitors that can significantly increase warfarin's blood levels^{4,11}

Fluconazole and other azole antifungals
Metronidazole
Trimethoprim (Cotrimoxazole)
Amiodarone
Paroxetine and other serotonin selective reuptake inhibitors