

Painful shoulder? Remote clinical management of a Field Guide with shoulder pain and loss of shoulder function in Antarctica

Gareth Jones, Mark I Johnson

Centre for Pain Research, School of Clinical and Applied Sciences, Leeds Beckett University, Leeds, UK

CASE STUDY

Please cite this paper as: Jones G, Johnson MI. Painful shoulder? Remote clinical reasoning of a Field guide with shoulder pain and loss of shoulder function in Antarctica. AMJ 2017;10(6):474–477.

<https://doi.org/10.21767/AMJ.2017.2986>

Corresponding Author:

Gareth Jones

Centre for Pain Research

School of Clinical and Applied Sciences

Leeds Beckett University, Leeds, LS1 3HE, UK

Email: g.j.jones@leedsbeckett.ac.uk

ABSTRACT

We report the case of a female Field Guide based at the British Antarctic Survey's Rothera Science Research Station on Adelaide Island, Antarctica who independently contacted a physiotherapist specialising in climbing related injuries (GJ) located in the UK. for a second opinion. The Field Guide was experiencing significant work difficulties due to shoulder pain and subsequent loss of function particularly in overhead activities. The case raises important issues about the medical management of Field Guides operating in extreme environments and remote locations.

Key Words

Subacromial impingement syndrome, Antarctica, remote workers, load

Implications for Practice:

1. What is known about this subject?

Subacromial impingement syndrome is a common presentation within the primary care setting but determining the seriousness of pathophysiology can be challenging.

2. What new information is offered in this case study?

Our case highlights challenges associated with diagnoses of musculoskeletal injuries in remote settings and the need to carefully monitor load and risk of injury.

3. What are the implications for research, policy, or practice?

External loading from work-related activities should be monitored in remote workers using simple time motion measurement tools.

Background

Field Guides are experienced mountaineers and climbers responsible for the safety and well-being of British Antarctic Survey professionals operating in the extremely harsh wilderness environment of Antarctica. The role of Field Guides is to safeguard British Antarctic Survey professionals from hazards they may encounter in the field such as crevasse crossings and to maintain the facilities in which the professionals operate. Field Guides routinely engage in strenuous physical activity and have an increased risk of injury.

Case details

Initially the Field Guide (a female aged 50 years) presented to the station medic with right shoulder pain and was diagnosed as having shoulder impingement and prescribed oral analgesics PRN. The pain abated during rest or reduced workload but was exacerbated during more active periods. One month later the Field Guide visited the American research station at Union Glacier, Antarctica for a medical consultation which confirmed shoulder impingement and she was treated with an intra-muscular injection of dexamethasone into the dorsogluteal site for pain relief. Over the next 6 months the Field Guide continued to work at Rothera despite persistent pain. The Field Guide self-managed pain with exercise and oral analgesics (codeine and diclofenac) and had regular reviews with the medic at Rothera who became concerned that there may be a tear in the rotator cuff following advice from the British Antarctic Survey's medical unit in the UK. Rothera did not possess the

necessary diagnostic equipment or expertise to carry out further investigations and it was not possible to return the Field Guide to the UK because it was the Antarctic winter. A decision was made to return the Field Guide to the UK. In several months when transport links were re-established post winter. Further deterioration in pain and function precipitated the Field Guide to seek a second opinion from a physiotherapist specialising in climbing related injuries (GJ). A consultation via Skype video was planned but poor internet connectivity meant that only audio telecommunication was possible.

Past medical history revealed no history of gross instability of the shoulder but there had been a previous fall with impact on the right shoulder that had occurred approximately one year before the current episode of right shoulder pain. The fall produced no visible trauma and medical attention was not sought. The differential diagnosis included the early stages of adhesive capsulitis, calcific tendonitis, and impingement with either a partial thickness or full thickness rotator cuff tear. Visceral pathology and cervical radiculopathy were ruled out because pain was localised under the acromion process and linked to the performance of specific moments. Pain was present when sleeping on the right side and evoked by unguarded movements and reaching overhead. The Field Guide was asked to perform a series of active movements including flexion, abduction and rotation and it was ascertained that the range of external rotation was good thus excluding capsulitis or frozen shoulder, the range of internal shoulder rotation was severely limited, consistent with a rotator cuff tear or calcific tendinitis. Abduction produced a 'painful arc' between 80–100 degrees that was rated as 8/10 (with 0 being no pain and 10 being the worst pain imaginable). There was no report of referred pain or paraesthesia. From these findings a diagnosis of subacromial impingement syndrome due to a partial tear of the supraspinatus and likely bursal hypertrophy and tendinopathy was made. As the internal rotation deficit may have been contributing to altered shoulder kinematics resulting in further reduction of the sub acromial space, there was potential for further damage to the rotator cuff and a risk of complete rupture of the supraspinatus. The Field Guide was advised to request to be returned to the UK for orthopaedic consultation as soon as possible (i.e., when winter ended so planes could land), in line with the original recommendation from the station Medic. Following the remote consultation, the Field Guide informed the British Antarctic Survey of the recommendation and she organised an orthopaedic consultation with a UK hospital to coincide with her return. A sub-acromial injection of triamcinolone acetonide and

steroid by the on-site medic would have been an appropriate treatment and might have been considered using Skype audio-visual guidance from an experienced Orthopaedic Surgeon. This was not possible and the Field Guide continued to carry some duties until repatriated, approximately two-months later.

In the UK, an orthopaedic consultant from a large teaching hospital organised a diagnostic assessment with a consultant radiographer. Plain radiographs confirmed no bony lesions and no calcific tendonitis. Ultrasound revealed a tense effusion within the long head of biceps tendon sheath, no macrocalcification, a thickened subacromial bursa, gross focal tendinosis, and a partial thickness tear with fissuring within the critical zone of the supraspinatus tendon which measured ~8mm deep and ~15mm wide. The orthopaedic consultant/consultant radiographer decided to inject the thickened bursa with a 10cc mixture of triamcinolone acetonide 40mg and local anaesthetic to alleviate pain and swelling. Treatment consisted of conservative physiotherapy rehabilitation and self-management to delay the necessity for surgery. Conservative rehabilitation included strengthening, stabilisation and proprioceptive exercise prescription, capsular stretches and joint mobilisations. Surgical intervention was planned if conservative and self-management failed.

What was learned from this case?

Our case highlights challenges associated with diagnoses of musculoskeletal injuries in remote settings where there is limited availability of diagnostic equipment and an absence of physiotherapy. The use of a Skype consultation is ideal in this situation but it was disappointing that the visual link was not possible due to a poor signal. Sub-clinically musculoskeletal overuse pathologies may remain undetected for several months with biological maladaptive change occurring through bouts of excessive load and insufficient periods of recovery. Thus, overuse pathologies are usually well established before an individual realises that there may be a problem, as demonstrated with our case. A Field Guide debilitated due to a routine musculoskeletal overuse injury may have serious consequences on on-going operations. Moreover, replacing a Field Guide may be financially expensive or impossible during the Antarctic winter. Medical staffs in the field tend to be generalists with specialisation in trauma rather than injuries associated with musculoskeletal overuse. The use of off-site expertise and telecommunication and consultation can aid difficult decisions about diagnosis, treatment and

extraction of individuals from remote extreme environments (Figures 1 and 2).

Subacromial impingement syndrome is a common presentation within the primary care setting and in sporting populations but determining the seriousness of pathophysiology can be challenging due to the complex interaction of dynamic and passive anatomical structures involved and the degree of inherent shoulder stability within individuals. The importance of physical tests to support diagnosis and clinical reasoning has recently been highlighted.¹ In particular the “Subacromial shoulder pain BESS/BOA Patient Care Pathway” is now being used routinely in the UK.² In our case, a positive painful arc test which involved the patient actively lifting their affected arm and reporting pain between 70–130 degrees provided valuable diagnostic information and demonstrates that simple physical tests can be conducted remotely. Nevertheless, there is an on-going debate about the diagnostic accuracy of symptom report, physical tests and medical imaging as systematic reviews have found insufficient evidence to support their use to detect lesions of the bursa, rotator cuff or labrum.^{3–5}

Field Guides undergo medical screening prior to leaving for Antarctica so that they are physically capable and medically fit to undertake the role. The complexities of musculoskeletal overuse pathologies that are asymptomatic mean that pre-visit screening may fail to detect Field Guides at risk of overuse injury during activities in Antarctica. Therefore, there is a need to carefully monitor load and risk of injury in the field in a similar manner to that for elite athletes.⁶ For example, external loading from engagement in work-related activities could be monitored using simple time motion measurement tools that record an individual’s physical exposure in an occupation environment. The Field Guide’s response to external loading (i.e., internal load) could be monitored using simple measurement tools that record perception of effort, sleep quality and psychological wellbeing. A tool to monitor risk of overuse injuries associated with chronic loading in extreme environments is clearly needed and could be adapted from those that exist for sport such as the Oslo Sports Trauma Research Centre questionnaire on health problems.⁷

Conclusion

Chronic overuse injuries often have an insidious onset which is initially manifested sub-clinically and eventually raised to the consciousness of the individual. Individuals may be operating for considerable periods of time whilst symptomatic and may not even consider themselves to be

in an injury state. Medical teams should consider routinely monitoring remote workers using tools designed to measure load.

References

1. Phillips N. Tests for diagnosing subacromial impingement syndrome and rotator cuff disease. *Shoulder Elbow*. 2014;6:215-221.
2. Kulkarni R, Gibson J, Brownson P, et al. Subacromial shoulder pain. *Shoulder Elbow*. 2015;7(2):135-143
3. Hanchard NCA, Lenza M, Handoll HHG, et al. Physical tests for shoulder impingements and local lesions of bursa, tendon or labrum that may accompany impingement. *Cochrane Database of Systematic Reviews*. 2013.
4. Unruh KP, Kuhn JE, Sanders R, et al. The duration of symptoms does not correlate with rotator cuff tear severity or other patient-related features: a cross-sectional study of patients with atraumatic, full-thickness rotator cuff tears. *J Shoulder Elbow Surg*. 2014 Jul;23(7):1052-8.
5. Dunn WR, Kuhn JE, Sanders R, et al. Symptoms of pain do not correlate with rotator cuff tear severity: a cross-sectional study of 393 patients with a symptomatic atraumatic full-thickness rotator cuff tear. *J Bone Joint Surg Am*. 2014;96(10):793-800.
6. Soligard T, Schweltnus M, Alonso JM, et al. How much is too much? (Part 1) International Olympic Committee consensus statement on load in sport and risk of injury. *Br J Sports Med*. 2016;50:1030-1041.
7. Clarsen B, Rønsen O, Myklebust G, et al. The Oslo Sports Trauma Research Center questionnaire on health problems: a new approach to prospective monitoring of illness and injury in elite athletes. *Br J Sports Med*. 2014;48(9):754-60.

ACKNOWLEDGEMENTS

We would like to thank the Field Guide for both providing the detail of her case and the image of the Rothera Station. Additionally, we would like to thank Primal Pictures for permission to use the anatomy image.

PEER REVIEW

Not commissioned. Externally peer reviewed.

CONFLICTS OF INTEREST

The authors declare that they have no competing interests.

FUNDING

None

PATIENT CONSENT

The authors, Jones G. and Johnson M.I., declare that:

1. They have obtained written, informed consent for the publication of the details relating to the patient(s) in this report.
2. All possible steps have been taken to safeguard the identity of the patient(s).
3. This submission is compliant with the requirements of local research ethics committees.

Figure 1: Rotator cuff anatomy

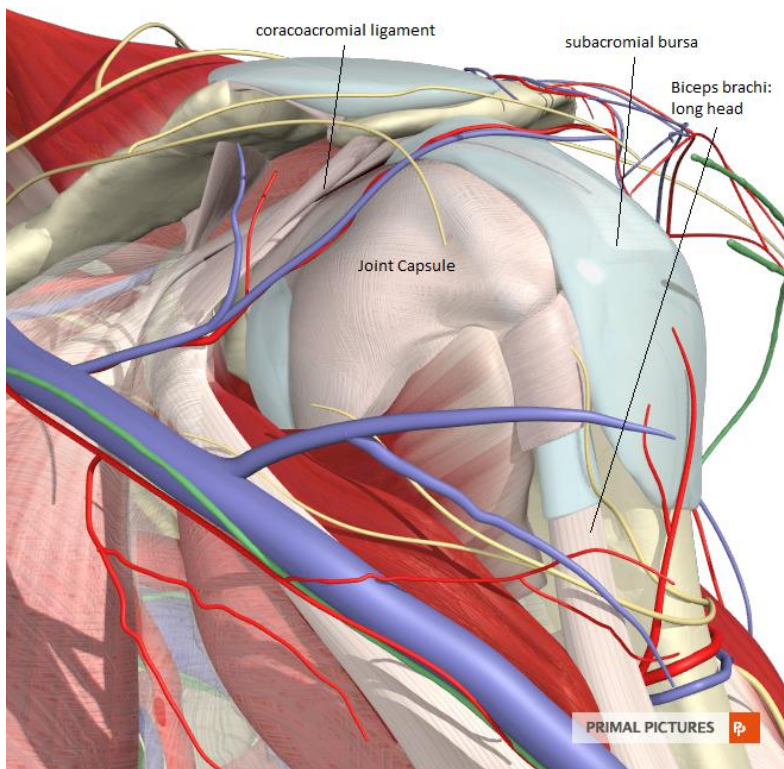


Figure 2: British Antarctic Survey's Rothera Science Research Station, Adelaide Island

