

## Giant sigmoid diverticulum: A case report

Pramod Durgakeri, Paul Strauss

Department of Surgery, Central Gippsland Health Service, Sale, VIC, Australia

---

### CASE STUDY

---

Please cite this paper as: Durgakeri P, Strauss P. Giant sigmoid diverticulum: A case report. AMJ 2015;8(3):85–88. <http://doi.org/10.21767/AMJ.2015.2279>

#### Corresponding Author:

Dr Pramod Durgakeri  
Central Gippsland Health Service  
155 Guthridge Parade  
Sale, Victoria 3850, Australia  
Email: [pramzd@yahoo.com](mailto:pramzd@yahoo.com)

---

### ABSTRACT

---

Sigmoid colon diverticulosis is commonly seen in both the surgical outpatient and emergency departments. Rarely, these sigmoid diverticulum, which usually range from 2–3mm to 2cm in size, can enlarge to more than 10 times. This is due to a ball-valve type mechanism that traps colonic gas inside the sigmoid diverticulum causing it to gradually enlarge. Patients with a giant sigmoid diverticulum (GSD) must be investigated thoroughly as two per cent of patients will present with a colonic carcinoma either within or distal to the GSD. Clinical symptoms of a GSD can range from chronic abdominal pain, altered bowel habits, abdominal distention, weight loss, bleeding, perforation, fistula formation, or bowel obstruction. CT and plain abdominal x-ray is the investigation of choice for its diagnosis. Barium enema is useful to determine the presence of a carcinoma within the GSD. Sigmoidoscopy is useful to rule out a distal colonic carcinoma. This is the first published case where nocturnal diarrhoea is the primary differentiating symptom in the patient. The treatment of choice for a GSD is complete resection of the diverticulum and/or the adjacent sigmoid colon. This can be performed with a primary anastomosis or a double-stage procedure.

#### Key Words

Giant sigmoid diverticulum, giant colonic diverticulum, phantom tumour

---

#### Implications for Practice:

##### 1. What is known about this subject?

Giant sigmoid diverticulum (GSD) is a very rare condition with only approximately 180 cases published in the literature. Characterised by a gigantic enlargement of a sigmoid diverticulum, it can cause chronic abdominal pain and distension, bleeding, and altered bowel habits. Patients can present with an intermittently palpable lower abdominal mass causing further confusion in the diagnosis of this phantom tumour.

##### 2. What new information is offered in this case study?

The case reported here is the first published case of GSD where the principal and differentiating symptom bringing this patient into our clinic is nocturnal diarrhoea.

##### 3. What are the implications for research, policy, or practice?

A patient with a GSD needs to be thoroughly investigated as approximately two per cent of patients with a GSD have a colonic cancer either within or distal to the diverticulum. This may change the treatment offered to the patient.

---

#### Background

Giant sigmoid diverticulum (GSD) are gigantic air-filled out-pouchings of the sigmoid colon. Approximately 90 per cent of these gigantic enlargements of a colonic diverticulum occur in the sigmoid colon.<sup>1</sup> GSD originate as the commonly seen sigmoid diverticulum that grows to an abnormally large size. Since they can be intermittently palpable in the lower abdomen, GSD is occasionally referred to as a “phantom tumour”. A sigmoid diverticulum can range in size from 2–3mm to 2cm.<sup>2</sup> The GSD can range from 4cm to 25cm in diameter.<sup>3</sup> This gigantic enlargement is thought to be due to a slow and gradual inflation of a sigmoid diverticulum by colonic gas. A ball-valve type mechanism present at the neck allows for the diverticulum to be inflated but does not

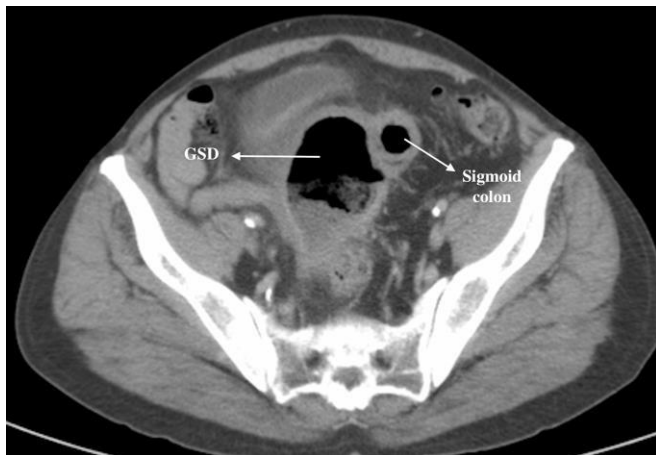allow the gas to exit.<sup>4</sup> Due to chronic inflammation the GSD may contain an abscess. The purulent content of the GSD can leak out causing loose bowel actions.

**Case details**

A 69-year-old man was referred to our surgical outpatient clinic with chronic abdominal cramps, relieved on opening his bowels. He complained of irregular bowel habits for a few years. He had undergone a colonoscopy two years prior to this presentation, which showed diverticular disease of the sigmoid colon and no other abnormality. He reported a few months of nocturnal diarrhoea; the patient found this the most distressing symptom. This nocturnal diarrhoea was found to occur every time the patient slept on his right side. This occasionally occurred when the patient was asleep, causing feculent incontinence.

On physical examination he had a slightly distended abdomen with an occasionally palpable lower abdominal mass and a normal per-rectal examination. A CT scan showed a large, thick-walled, inflamed collection to the right of the sigmoid colon (Figure 1).

**Figure 1: A thick-walled collection to the right of the sigmoid colon**

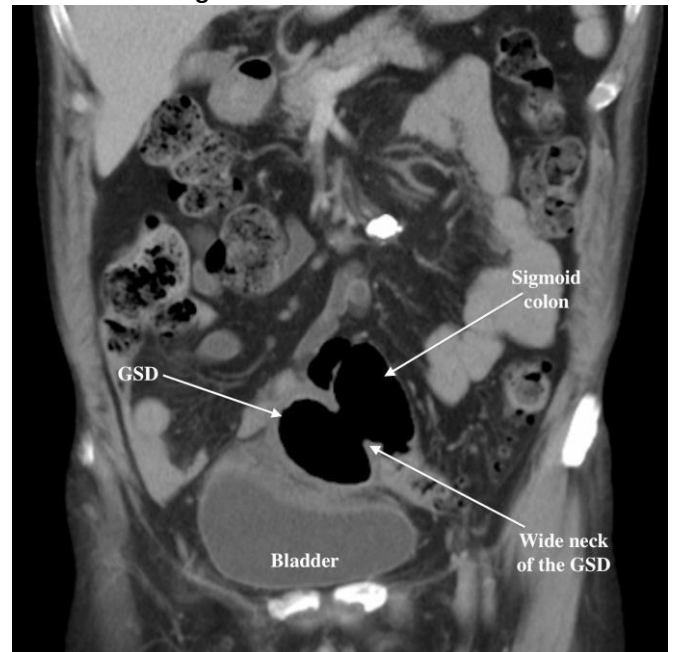


This “collection” appeared to have a large opening into the sigmoid colon (Figure 2). The differential diagnosis at this point was a large pelvic abscess secondary to a perforated sigmoid diverticulum, bowel duplication, Meckel’s, or duodenal diverticulum. A barium enema study clearly demonstrated the 6cm diameter giant diverticulum located to the right of the sigmoid colon (Figure 3).

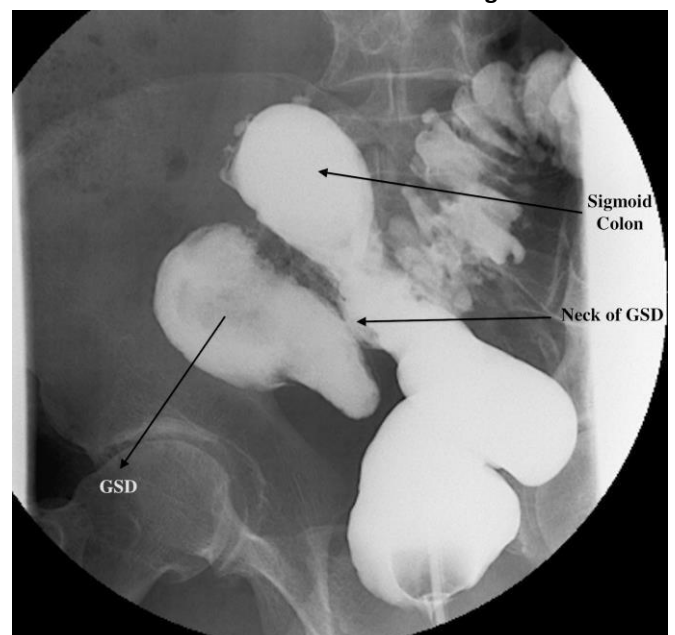
This diverticulum had a 2.5cm neck and was connected to the sigmoid colon. This patient underwent an elective high anterior resection with primary anastomosis. Intra-operatively, we noted that the GSD was adherent to the bladder and showed signs of inflammation. The patient had

an uneventful recovery post-operatively. The resected segment of sigmoid colon showed extensive diverticulosis and a wide-necked giant diverticulum. This false diverticulum displayed the characteristic out-pouching of the mucosa through the muscularis propria into the serosal adiposal tissue, unlike a true diverticulum, which includes the mucosa, muscularis propria, and adventitia. A focal area of necrosis with acute inflammation with fibrinous exudate was evident. This specimen was negative for malignancy.

**Figure 2: A CT scan image demonstrating the GSD in relation to the sigmoid colon and the bladder**



**Figure 3: A barium enema demonstrating the smooth wall of the GSD and its neck in relation to the sigmoid colon**



## Discussion

GSD is a very rare condition with approximately 180 published cases.<sup>5</sup> Since its first description in 1946 by Bonvin and Bonte,<sup>5</sup> a variety of symptoms have been reported by patients. These can range from chronic abdominal pain, altered bowel habits, abdominal distention, weight loss,<sup>5</sup> bleeding, perforation, or bowel obstruction.<sup>1</sup> We report a case of a patient with persistent nocturnal diarrhoea progressively worsening. To our knowledge, this symptom associated with a GSD has not been published in the literature to date. Due to the large size of the GSD, the volume of diarrhea can be large. This symptom can also be intermittent as the ball-valve mechanism of the GSD occasionally prevents this from occurring. Our patient reported this symptom when lying on his right side. This was due to the leakage of the purulent content of the GSD secondary to the chronic inflammation. When he was lying on his right side, the liquid component of the GSD leaked out causing this symptom. During the patient's barium enema study, the radiographer instructed the patient to lie on his left side to allow the GSD to fill up with the contrast material.

All giant colonic diverticulae can be classified into three types based on their histological appearance:<sup>1</sup>

Type I: pseudo-diverticulum or false diverticulum (22 per cent) contain submucosa and mucosa. They enlarge gradually, are lined with chronic granulation and fibrous tissue with remnants of muscularis mucosa; for example, GSD.

Type II: inflammatory diverticulum (66 per cent) do not contain any layers of bowel. This is a walled-off abscess cavity secondary to a localised perforation. This communicates with the bowel and gradually enlarges. This diverticulum contains fibrous scar tissue.

Type III: true diverticulum (12 per cent) contains all the layers of the bowel. This is usually a continuation of the bowel;<sup>1</sup> for example, Meckel's diverticulum.

Abdominal CT scan and plain abdominal x-ray are the investigations of choice for definitive diagnosis of a GSD.<sup>1</sup> The CT will demonstrate a thick-walled, air-filled cavity in close proximity to the affected colon. The plain abdominal x-ray will demonstrate a solitary air-filled cystic structure in the pelvis.<sup>1</sup> A barium enema will aid in determining the precise size and texture of the wall of the GSD. Patients are ideally positioned on their left side to encourage the GSD to fill with the contrast material. Occasionally, only a small

amount of contrast may enter the GSD, but this is usually sufficient to identify the sigmoid colon and the GSD in communication with it. This contrast study should demonstrate the smooth margin of round or oval-shaped structure with a homogenous radiolucency (Figure 3).

Approximately two per cent of GSD patients have a carcinoma within or distal to the diverticulum.<sup>6</sup> If the wall of the GSD does not appear to be smooth in appearance, one should have a high suspicion for the presence of a carcinoma within the GSD. This is usually confirmed postoperatively during the histo-pathological evaluation of the specimen. The surgeon will need to resect the GSD with adequate surgical margins. A carcinoma distal to the GSD, causing sufficient colonic lumen narrowing, will lead to an increase in colonic pressures in a sigmoid diverticulum—this will cause the sigmoid diverticulum to enlarge.<sup>5</sup> A flexible or rigid sigmoidoscopy will aid with the diagnosis of a mass distal to the GSD in cases where a distal carcinoma is highly suspected. The treatment of choice for a GSD is complete resection of the diverticulum and/or the adjacent sigmoid colon with a primary anastomosis. In cases of a complicated GSD with a perforation, abscess, or fistulation to the bladder, a two-stage procedure such as a Hartmann's procedure is acceptable.<sup>1</sup>

## Conclusion

Patients with known sigmoid diverticulosis who present with abdominal distention and an occasionally palpable lower abdominal mass with altered bowel habits should be investigated for a GSD. Occasionally, the only symptom reported by a patient may be the nocturnal diarrhoea as patients usually tolerate abdominal pain and distention but the nocturnal diarrhoea is most distressing. A CT scan and plain abdominal X-ray are most useful in its diagnosis. Once diagnosed, a carcinoma within or distal to the GSD must be ruled out with a barium enema and or sigmoidoscopy prior to surgical management, as this may alter the procedure offered to the patient. Complete resection of the GSD with a primary anastomosis and adequate surgical margins is the treatment of choice. In complicated cases with localised perforation or abscess, a double-stage procedure such as a Hartmann's procedure is acceptable.

---

## References

1. Kam JC, Doraiswamy V, Spira RS. A rare case presentation of a perforated giant sigmoid diverticulum. *Case Rep Med.* 2013;2013:1.
2. Horton KM, Corl FM, Fishman EK. CT evaluation of the colon: Inflammatory disease. *RadioGraphics.* 2000;

20:399-418.

3. Mainzer F, Minagi H. Giant sigmoid diverticulum. *Am J Roentgenol Radium Ther Nucl Med.* 1971;113(2):352-4.
4. Nano M, De Simone M, Lanfranco G, Bronda M, Lale-Murix E, et al. Giant sigmoid diverticulum. *Panminerva Med.* 1995;37:44-8.
5. Sasi W, Hamad I, Quinn A, Nasr AR. Giant sigmoid diverticulum with coexisting metastatic rectal carcinoma: a case report. *J Med Case Rep.* 2010;4:324.
6. Custer TJ, Blevins DV, Vara TM. Giant colonic diverticulum: a rare manifestation of a common disease. *J Gastrointest Surg.* 1999;3(5):543-8.

### **PEER REVIEW**

Not commissioned. Externally peer reviewed.

### **CONFLICTS OF INTEREST**

The authors declare that they have no competing interests.

### **PATIENT CONSENT**

The authors, Durgakeri P, Strauss P, declare that:

1. They have obtained written, informed consent for the publication of the details relating to the patient(s) in this report.
2. All possible steps have been taken to safeguard the identity of the patient(s).
3. This submission is compliant with the requirements of local research ethics committees.