

An unorthodox innervation of the gluteus maximus muscle and other associated variations: A case report

Suhani Sumalatha, Antony Sylvan D Souza, Jitendra Singh Yadav, Sachendra Kumar Mittal, Amoldeep Singh, Sushma R Kotian

Department of Anatomy, Kasturba Medical College Manipal University, Manipal, India

CASE STUDY

Please cite this paper as: Sumalatha S, D Souza AS, Yadav JS, Mittal SK, Singh A, Kotian SR. An unorthodox innervation of the gluteus maximus muscle and other associated variations: A case report. AMJ 2014;7(10):419-422. <http://doi.org/10.21767/AMJ.2014.2225>

Corresponding Author:

Sushma R Kotian
Dept. of Anatomy, Kasturba Medical College
Manipal University, Manipal-576104, India
Phone- +91-820-2922327 (Office)
Fax- +91-820-2570061
Email: sushma.rk@manipal.edu

ABSTRACT

Knowledge of peripheral nerve morphology, location, and variation is important for facilitating appropriate diagnosis and intervention. We present a unique case of absence of the inferior gluteal nerve and high division of the sciatic nerve. In this instance, the common peroneal nerve was found piercing the piriformis muscle and emerging distally in the form of two trunks: thin medial and thick lateral. The medial trunk presented an interesting course, supplying the gluteus maximus muscle before joining the lateral trunk to form the common peroneal nerve. Additionally, the arteria nervi ischiadisci was also observed accompanying and supplying the tibial nerve passing inferior to the piriformis. These variations are important for clinicians and surgeons for some radiological diagnoses and surgical procedures in the lower limb.

Key Words

Gluteus maximus, sciatic nerve, common peroneal nerve, inferior gluteal nerve, piriformis, arteria nervi ischiadisci

Implications for Practice:

1. What is known about this subject?

The occurrence of the high division of the sciatic nerve is common and its clinical implications are previously described.

2. What new information is offered in this case study?

The present study reports the co-existence of multiple variations; i.e., high division of the sciatic nerve along with other rare variations like absence of the inferior gluteal nerve, innervation of the gluteus maximus muscle by the common peroneal nerve, and the persistence of the arteria nervi ischiadisci.

3. What are the implications for research, policy, or practice?

Co-existence of all these variations in the gluteal region is unusual and warrants attention as this is the area of frequent surgical intervention. The described variations may lead to adverse effects such as nerve injury during deep intramuscular injections in the gluteal region, failed sciatic nerve block in anaesthesia, and injury during posterior hip operations.

Background

The sciatic nerve is the largest branch of the sacral plexus and is formed by the tibial (ventral branches of the ventral rami of L4, L5, S1, S2, and S3 spinal nerves) and common peroneal components (dorsal branches of the ventral rami of L4, L5, S1, and S2 spinal nerves). It begins in the pelvis and leaves the pelvic cavity through the greater sciatic foramen to enter the gluteal region inferior to the piriformis muscle. Normally it terminates at the superior angle of the popliteal fossa by dividing into the tibial and common peroneal nerve. However, it may also terminate within the pelvis. In such cases, the tibial and the common peroneal nerves may leave the pelvis through different routes.

The inferior gluteal nerve (dorsal branches of the ventral rami of L4, L5, S1, and S2 spinal nerves) is another

important structure encountered in the gluteal region emerging inferior to the piriformis. This nerve normally supplies the gluteus maximus muscle.¹ Co-existence of all these variations is rare and not frequently reported.² Such variations warrant attention as this area is commonly involved in surgical interventions, is a reported site of nerve injury during deep intramuscular injections³ or nerve block during anaesthesia, and is known to be injured during posterior hip operations.⁴

Case details

During routine anatomical dissection for the undergraduate medical students in the Department of Anatomy, Kasturba Medical College, Manipal, India, we encountered an extremely rare variation in the right gluteal region of a 68-year-old male cadaver. Early proximal division of the sciatic nerve into the common peroneal nerve and tibial nerve occurred, with the common peroneal nerve emerging into the gluteal region by passing between the two heads of the piriformis muscle and the tibial nerve passing inferior to the piriformis. The tibial nerve was accompanied by the inferior gluteal artery, posterior cutaneous nerve of the thigh, pudendal nerve, and the internal pudendal vessels. Interestingly, the inferior gluteal nerve was absent, and the gluteus maximus muscle was innervated by the common peroneal nerve in the gluteal region.

The common peroneal nerve entered the gluteal region in the form of two trunks: a thin medial and a thick lateral trunk. The thin medial trunk was observed to innervate the gluteus maximus muscle. This medial trunk, immediately after supplying the muscle, joined the lateral trunk to form a large trunk of the common peroneal nerve (Figure 1). No further variation was detected in the course and termination of the common peroneal nerve. Additionally, the arteria nervi ischiadici was also observed in the present case arising from the inferior gluteal artery and accompanying and supplying the tibial nerve.

Discussion

The sciatic nerve is the thickest nerve of the body and is classically the only nerve of the posterior compartment of the thigh, subject to morphological variation.^{1,2} It is formed by the variable contribution from the dorsal and the ventral division from the sacral plexus in the pelvic cavity. In most cases the sciatic nerve enters the gluteal region below the lower border of the piriformis along with the inferior gluteal nerve and vessels, the posterior cutaneous nerve of the thigh, and the pudendal vessels and nerve.¹

In most instances (83 per cent), the sciatic nerve terminates as the common peroneal and tibial nerves in or near the

popliteal fossa.⁵ However, termination of the sciatic nerve in the pelvic cavity, the gluteal region, and the upper thigh is also reported in the literature.²

Figure 1: Multiple variations in the right gluteal region

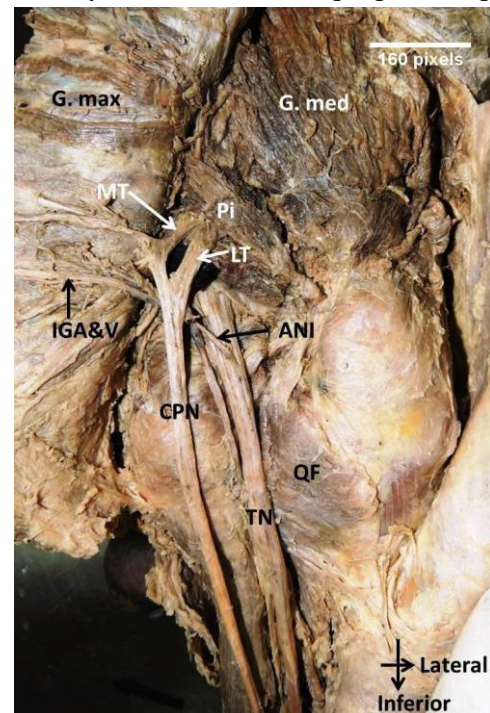


Figure showing high division of the sciatic nerve into the tibial (TN) and common peroneal (CPN) nerves, and the absence of the inferior gluteal nerve. The CPN emerged into the gluteal region passing between the two heads of piriformis muscle (Pi) in the form of two trunks, thick lateral (LT) and thin medial (MT). The TN passed anterior to the piriformis. The MT innervated the gluteus maximus muscle (G. max) before joining the lateral trunk to form a common trunk of the CPN. Arteria nervi ischiadici (ANI) was also observed, arising from the inferior gluteal artery that accompanied and supplied the TN. G. med—Gluteus medius, QF—Quadratus femoris, IGA&V—Inferior gluteal vessels.

High division of the sciatic nerve into the tibial and common peroneal nerve is the most commonly encountered variation overall and is observed in 48 per cent of cases.^{6,7} According to Datta,⁸ at times the ventral and the dorsal branches from the sacral plexus may remain separate and in such cases the dorsal branch, which forms the common peroneal nerve, pierces the piriformis muscle and the ventral branch, which forms the tibial nerve, passes deep to the piriformis muscle.⁸ In the present case high division of the sciatic nerve was observed with the common peroneal nerve passing between the two heads of the piriformis and tibial nerve passing inferior to it. This variant relationship between the branches of the sciatic nerve and the piriformis muscle was previously reported by Natsis et al.⁹ According to them, in 4.1 per cent of the cases, the common peroneal nerve passed between the piriformis and the tibial nerve

inferior to it. This could be associated with piriformis syndrome, and therefore identification of the additional bellies of the piriformis is necessary for adequate sciatic nerve decompression in cases where compression of the sciatic nerve in the gluteal region is diagnosed.⁹

The inferior gluteal nerve normally arises inferior to the piriformis and generally ends by supplying the gluteus maximus muscle and has no cutaneous branches;¹ however, this nerve may also show variations.^{10,11} Authors in the past have reported a case of high division of the sciatic nerve with an anomalous double root of the inferior gluteal nerve emerging along both the upper and lower borders of the piriformis muscle to form the inferior gluteal nerve to supply the gluteus maximus muscle.¹⁰ Yan et al. also reported a case of emergence of the inferior gluteal nerve and vessels along the superior border of the piriformis muscle with an incidence of 4.26 per cent of the Japanese population.¹¹ Bhattacharya et al. reported multiple variations in the left gluteal region where they noted double piriformis, high division of the sciatic nerve, and dual nerve supply of the gluteus maximus. The additional supply to the gluteus maximus was derived from the common peroneal nerve.¹² In yet another case, Jacomo et al. reported the origin of the inferior gluteal nerve from the common peroneal nerve.¹³ High division of the sciatic nerve with an additional communicating branch connecting the tibial and the common peroneal nerves below the piriformis was also observed in this study.¹³ The present case is unique as the inferior gluteal nerve was absent and the gluteus maximus muscle was entirely supplied by a short, thin medial trunk from the common peroneal nerve.

The arteria nervi ischiadisci, which may participate in collateral circulation generally accompanies and supplies the sciatic nerve. It is a remnant of the axis artery of the lower limb.¹ In the present case, the artery accompanied and supplied the tibial nerve. This may be due to the high division of the sciatic nerve.

Conclusion

The anatomical knowledge of the co-existence of such variations may be useful in clinical practice, especially in cases such as ongoing gluteal pain or discomfort, and is therefore useful for musculoskeletal practice, diagnostic and interventional radiological procedures, and surgical procedures in this region. Preoperative nerve imaging in the gluteal region is recommended as an adjunct to help avoid potential complications when it is considered that there may be potential risk associated with a given procedure, particularly in instances that do not fit classic textbook

descriptions of sensory loss or innervation, as variations in nerve morphology in the gluteal region are common.

References

1. Standring S. *Gray's Anatomy*, 40th edition, London Press; 2008. p. 1369–71,1378, 1384.
2. Bergman RA, Thomson SA, Afifi AK, Saadash FA. *Compendium of human anatomical variations*. Urban and Schwarzenberg, Germany; 1988.
3. Cornwall J. Are Nursing Students Safe When Choosing Gluteal Intramuscular Injection Sites? *Australas Med J* 2011;4(6):315–21.
4. Patel S, Shah M, Vora R, Zalawadia A, Rathod Sp. A variation in the high division of the sciatic nerve and its relation with piriformis muscle. *Natl J Med Res* 2011;1(2):27–30.
5. Beaton LE, Anson BJ. The relation of the sciatic nerve and of its subdivisions to the piriformis muscle. *Anat Rec* 1937;70(1):1–5.
6. Nayak S. An unusual case of trifurcation of the sciatic nerve. *Neuroanatomy* 2006;5:6–7.
7. Güvençer M, İyem C, Akyer P, Tetik S, Naderi S. Variations in the high division of the sciatic nerve and relationship between the sciatic nerve and the piriformis. *Turk Neurosurg* 2009;19:139–44.
8. Datta AK. Blood vessels and nerves of the pelvis. In: *Essentials of human anatomy, Thorax and Abdomen*, 7th ed. Kolkata: Current Books International; 2006. p. 353–55.
9. Natsis K, Totlis T, Konstantinidis GA, Paraskevas G, Piagkou M, Koebeke J. Anatomical variations between the sciatic nerve and the piriformis muscle: a contribution to surgical anatomy in piriformis syndrome. *Surg Radiol Anat* 2014;36(3):273–80.
10. Pavai J, Nayak S. A case of bilateral high division of sciatic nerve with a variant inferior gluteal nerve. *Neuroanatomy* 2006;5:33–4.
11. Yan J, Takechi M, Hitomi J. Variations in the Course of the Inferior Gluteal Nerve and Artery: A Case Report and Literature Review. *Surgical Science* 2013;4:429–32.
12. Bhattacharya S, Chakraborty P, Majumdar S, Dasgupta H. Different neuromuscular variations in the gluteal region. *IJAV* 2013;6:136–9.
13. Jacomo AL, Martinez CAR, Saleh SO, Andrade M, Akamatsu FE. Unusual Relationship between the Piriform Muscle and Sciatic, Inferior Gluteal and Posterior Femoral Cutaneous Nerves. *Int J Morphol* 2014;32(2):432–4.

ACKNOWLEDGEMENTS

We are grateful to the body donors who have so graciously gifted their bodies to medical science.

PEER REVIEW

Not commissioned. Externally peer reviewed.

CONFLICTS OF INTEREST

The authors declare that they have no competing interests.