

## Congenital middle mesocolic hernia: A case report

Narayanasamy S Kannan, Kannan Usha, Thangamani Arun, Mohamedhanif P  
Naseeruddin, Petchiappan C Ganesh Babu, Selvaraj Karthikesh

Mahatma Gandhi Medical College & Research Institute, Pondicherry, India

### CASE STUDY

Please cite this paper as: Kannan NS, Usha K, Arun T, Naseeruddin MP, Ganesh Babu PC, Karthikesh S. Congenital middle mesocolic hernia: A case report. AMJ 2014;7(11):432-435.

<http://doi.org/10.21767/AMJ.2014.2179>

#### Corresponding Author:

Dr NS Kannan

Mahatma Gandhi Medical College & Research Institute,  
Pondicherry, India, 607402.

Email: [drnskannan@yahoo.co.in](mailto:drnskannan@yahoo.co.in)

### ABSTRACT

Internal hernia is herniation of a viscus, usually in the small bowel, through a normal or abnormal aperture within the peritoneal cavity. Its incidence has been reported to be one to two per cent. Internal hernias are classified based on location, and the hernial orifice can be either congenital or acquired. Paraduodenal hernias are the most common type (53 per cent). Paraduodenal hernia is often a misnomer and is referred to as a mesocolic hernia. Left and right mesocolic hernias are common, while middle and transverse types are rare. We are reporting a rare congenital middle mesocolic hernia presenting as a complete transection of the small intestine due to blunt injury to the abdomen.

#### Key Words

Paraduodenal, internal hernia, blunt injury abdomen

#### Implications for Practice:

##### 1. What is known about this subject?

Left and right mesocolic hernias are common, while middle and transverse types are rare. A congenital middle mesocolic hernia without malrotation of the gut is a rare anomaly. Blunt injury trauma to the abdomen resulting in a rupture of the small intestine near the fixed loops like the

duodeno jejunal and the ileo caecal junction is common due to intra-abdominal and intraluminal pressure changes during traumatogenesis.

##### 2. What new information is offered in this case study?

Our case describes a rare congenital middle mesocolic hernia presenting as a complete transection of the small intestine due to blunt injury to the abdomen.

##### 3. What are the implications for research, policy, or practice?

Knowledge of internal hernias and biomechanics of blunt trauma to the abdomen is required for the surgeon to identify such an entity and institute prompt surgical intervention to reduce morbidity and mortality.

### Background

Internal hernias may be either congenital or acquired. Their incidence has been reported to be one to two per cent.<sup>1-6</sup> Among the congenital internal hernias, paraduodenal hernias are the most common type (53 per cent).<sup>7-9</sup> Paraduodenal hernia is often considered a misnomer and is referred to as a mesocolic hernia.<sup>10</sup> Seventy-five per cent of mesocolic hernias occur on the left, while 25 per cent occur on the right.<sup>11-14</sup> Middle mesocolic hernia is a rare entity.<sup>15</sup> Thus far, only one or two incidents have been reported in the medical literature. Intestinal injury has been found in 5-16 per cent of blunt abdominal trauma.<sup>16-18</sup> In blunt abdominal trauma compression forces and deceleration forces play a role making relatively fixed loops of the small intestine like the duodeno jejunal and ileo caecal junctions.<sup>19</sup> In our case a loop of jejunum ileal junction presenting in the middle mesocolic hernia has suffered the brunt of attack due to its proximity to the assailing forces when compared to the duodeno jejunal and ileo caecal junctions, in addition to its relatively fixed location within the congenital middle mesocolic hernia.

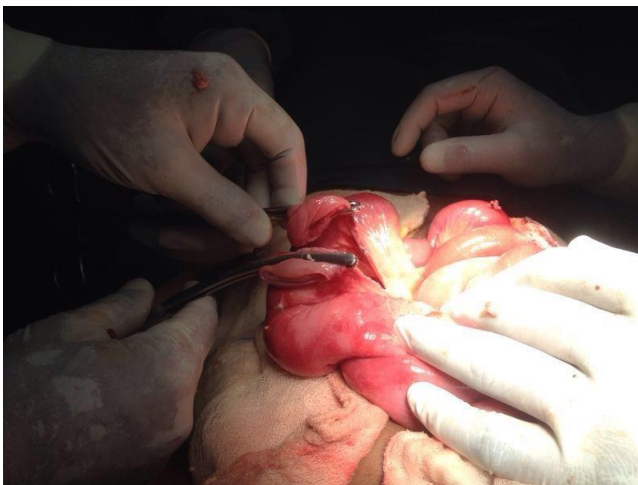### Case details

A 14-year-old boy presented with a history of blunt injury of the upper abdomen due to the impact of the handle bar of a bicycle from an alleged road traffic accident six hours prior

to admission. Past history did not reveal any illness relating to intestinal issues suffered by the patient prior to this accidental blunt trauma. General examination revealed stable vitals. On examination the abdomen was distended with generalised guarding, liver dullness was obliterated, and shifting dullness was present. Provisional diagnosis of the hollow viscus perforation was made. A plain X-ray of the abdomen erect showed air under both domes of the diaphragm with fluid levels.

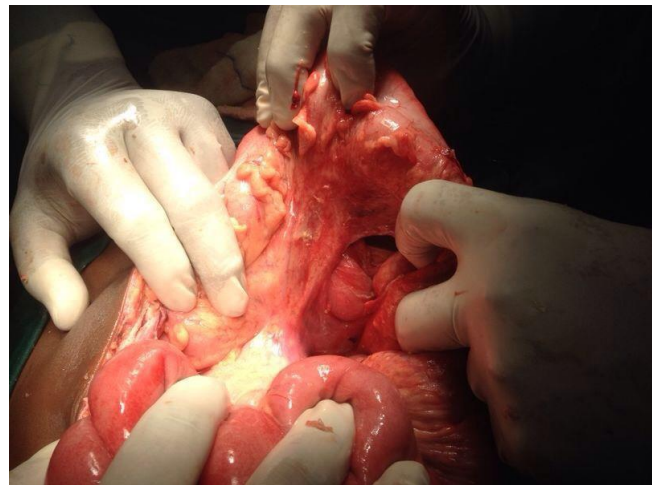
After routine investigations and correction of fluid and electrolyte imbalance, the patient was taken to the operating room for an emergency laparotomy under general anaesthesia. An upper midline abdominal incision was made. Intraoperative findings revealed 1500ml of faecal peritoneal fluid, due to a completely transected loop of the jejunum ileal junction presenting in the supracolic compartment through a congenital rent in the transverse mesocolon to the left of the middle colic artery (Figure 1).

**Figure 1: Transected loop of jejunum ileal junction in the supracolic compartment**



There was no evidence of malrotation of the gut. All the infected peritoneal fluid was evacuated. The ruptured loop of the jejunum ileal junction was easily reduced back to the infracolic general peritoneal cavity. After reduction, the rent in the middle of the transverse mesocolon was inspected and found to be congenital in nature with thickened intact margins (Figure 2). Primary end-to-end anastomosis of the small intestine was done along with closure of the defect in the transverse mesocolon with 1-0 vicryl. The abdomen was closed in layers with bilateral tube drains after thorough peritoneal toilette. The postoperative period was uneventful with the usual postoperative orders. He was discharged on the 11<sup>th</sup> day post-operation.

**Figure 2: Congenital rent in the middle of the transverse mesocolon with thickened intact margins**



## Discussion

Internal hernias are defined as herniation of a viscus, usually in the small bowel, through a normal or abnormal aperture within the peritoneal cavity. These hernias may be either congenital or acquired. The incidence of internal hernias has been reported to be one to two per cent.<sup>1,2</sup> This herniation may be persistent or intermittent. An internal hernia is a rare cause of small bowel obstruction with a reported incidence of 0.2–0.9 per cent.<sup>3</sup> Pathologic defects of the mesentery and visceral peritoneum, which are caused by congenital mechanisms, may be associated with malrotation of the gut.<sup>4</sup> The acquired variety may occur following trauma, operation, and inflammation.<sup>5,6</sup> Internal hernias are classified based on location, and the hernial orifice can be either congenital or acquired. The locations and relative frequencies of internal hernias are as follows: paraduodenal, 53 per cent; pericecal, 13 per cent; foramen of Winslow, 8 per cent; transmesenteric and transmesocolic, 8 per cent; pelvic and supravescical, 6 per cent; sigmoid mesocolon, 6 per cent; and transomental, 1–4 per cent.<sup>7-9</sup>

Internal hernias are often misdiagnosed, because of their rarity, with subsequent significant morbidity. Paraduodenal hernia, the most common type, is often considered a misnomer and is referred to as a mesocolic hernia.<sup>10</sup> Seventy-five per cent of paraduodenal hernias occur on the left, while 25 per cent occur on the right.<sup>11-13</sup> The left mesocolic hernia originates at the fossa of Landzert, which is just lateral to the fourth segment of the duodenum and behind the inferior mesenteric vein (IMV) and ascending left colic artery.<sup>14</sup> The right mesocolic hernia protrudes into the ascending mesocolon, involving the fossa of Waldeyer, behind the superior mesenteric artery and inferior to the

third portion of the duodenum,<sup>13</sup> is also known as the Marrakesh hernia.

Middle mesocolic hernias are very rare and congenital mesocolic hernias are extremely rare.<sup>15</sup> Congenital middle mesocolic hernias occur through a congenital rent in the middle portion of the transverse mesocolon to the left of the middle colic artery without malrotation of the gut as in our case. In the transverse congenital mesocolic hernia, the transverse colon is invaginated behind the superior mesenteric artery and the mesentery. The duodenum is anterior to the superior mesenteric artery.

Intestinal injury has been found in 5–16 per cent of patients undergoing laparotomy after blunt abdominal trauma.<sup>16–18</sup>

Blunt injury to the intra-abdominal structures, mainly the hollow viscus, can be classified into two primary mechanisms—compression forces, and deceleration forces.<sup>19</sup> A third mechanism of crushing force is also suggested affecting mainly intra-abdominal solid organs in addition to compression forces and deceleration forces. Complete transection of the small intestine especially at the relatively fixed points like the duodeno jejunal and the ileo caecal junctions are mainly due to compression forces and deceleration forces.

In our case, a loop of the jejuno ileal junction presenting in the middle mesocolic hernia has suffered the brunt of the attack due to its proximity to the assailing forces when compared to the duodeno jejunal and ileo caecal junctions, in addition to its relatively fixed location within the congenital middle mesocolic hernia. Preoperative diagnosis of the silent middle mesocolic hernia is not possible unless it is presenting with complications like intestinal obstruction, perforation, or gangrene either due to constricting the neck of the sac, or due to adhesions, or rarely due to trauma as in our case. Occasionally it might be an incidental finding in imaging modalities or laparotomy done for other reasons. Knowledge of all these forces and biomechanics is essential for early diagnosis and prompt, efficient management of such cases to reduce morbidity and mortality.

## Conclusion

A congenital middle mesocolic hernia is very rare. It may be silent or it may present with complications of obstruction, strangulation, or gangrene in the intestine. Or it may even present as a rupture in the intestine due to blunt trauma in the abdomen, as in our case. A strong suspicion of the possibility of such a rare congenital anomaly and knowledge of biomechanics of blunt trauma to the abdomen is required for the surgeon to identify such an entity and

institute prompt surgical intervention to reduce morbidity and mortality.

---

## References

1. Yokota T, Yamada Y, Murakami Y, Yasuda M, Teshima S, Kunii Y, et al. Emergency abdominal surgery for sigmoid mesocolic hernia. *Am J Emerg Med* 2002;20:137–8.
2. Munir A, Saleem SM, Hussain S. Paraduodenal hernia: A case report. *J Pak Med Assoc* 2004;54:162–3.
3. Li JC, Chu DW, Lee DW, Chan AC. Small-bowel intestinal obstruction caused by an unusual internal hernia. *Asian J Surg* 2005;28:62–4.
4. Zimmerman LM, Laufman H. Intraabdominal hernias due to developmental and rotational anomalies. *Ann Surg.* 1953 Jul;138(1):82-91.
5. Ghahremani GG. Abdominal and pelvic hernias. In: Gore RM, Levine MS, eds. *Textbook of Gastrointestinal Radiology*. 2nd ed. Philadelphia: Saunders: 2000;1993–2009.
6. Newsom BD, Kukora JS. Congenital and acquired internal hernias: unusual causes of small bowel obstruction. *Am J Surg* 1986;152:279–85.
7. Ghahremani GG. Internal abdominal hernias. *Surg Clin North Am* 1984;64:393–406.
8. Hanssmann GH, Morton SA. Intra abdominal hernia. *Arch Surg* 1939;39:973–86.
9. Sufian S, Matsumoto T. Intestinal obstruction. *Am J Surg* 1975;130:9–14.
10. Kihne M, Ramanujam TM, Sithasanan N. Mesocolic hernia: a rare cause of intestinal obstruction in childhood. *Med J Malaysia*. 2006 Jun;61(2):251-3.
11. Blachar A, Federle MP, Dodson SF. Internal hernia: clinical and imaging findings in 17 patients with emphasis on CT criteria. *Radiology* 2001;218:68–74.
12. William H, Rohan J. Abdominal hernias and their complications, including gastric volvulus. In: Sleisenger and Fordtran's *Gastrointestinal and Liver disease*, 7th ed. Philadelphia: W. B. Saunders, 2002, pp. 381–2.
13. Eric R, Oscar R, Mitchel K. Paraduodenal hernia: a report of two cases. *Am Surg* 2001;67:733–6.
14. Bartlett M, Wang C, William H. The surgical management of paraduodenal hernias. *Ann Surg* 1968;168:249–54.
15. Licciardello A, Rapisarda C, Conti P, Trombatore G. Small Bowel Obstruction Caused by an Unusual Variant of Paraduodenal Hernia. The "Middle Congenital Mesocolic Hernia": Case Report. *J Gastrointest Surg* 2014 Apr 23. doi: 10.1007/s11605-014-2527-z
16. Griswold RA, Collier HS. Blunt abdominal trauma. *Int Abstr Surg* 1961;112:309.
17. Hunt KE. Garrison RN, Fry DE. Perforating injuries of the

gastrointestinal tract following blunt abdominal trauma. *Am Surg* 1980;46:100–4.

18. Bergqvist D, Hedelin H, Karlsson G, Lindblad B, Matzsch T. Intestinal trauma (analysis of 101 cases). *Acta Chir Scand* 1981;147:625–9.
19. Salomone JA, Salomone JP. Abdominal Trauma, Blunt. Available at e medicine at Web MD. Accessed on 2<sup>nd</sup> Oct 2009.

### **PEER REVIEW**

Not commissioned. Externally peer reviewed.

### **CONFLICTS OF INTEREST**

The authors declare that they have no competing interests.

### **PATIENT CONSENT**

The authors, Kannan NS, Kannan U, Arun T, Naseeruddin MP, Ganesh Babu CP, Karthikesh S, declare that:

1. They have obtained written, informed consent for the publication of the details relating to the patient(s) in this report.
2. All possible steps have been taken to safeguard the identity of the patient(s).
3. This submission is compliant with the requirements of local research ethics committees.