



Spontaneous coronary artery dissection causing myocardial infarction in an 18-year-old man: A case report

Yan Herry, Alvin Tonang, Victor Herlambang, Novi Anggriyani

Department of Cardiology and Vascular Medicine, Faculty of Medicine Diponegoro University/Dr. Kariadi General Hospital, Semarang, Central Java, Indonesia

CASE REPORT

Please cite this paper as: Herry Y, Tonang A, Herlambang V, Anggriyani N. Spontaneous coronary artery dissection causing myocardial infarction in an 18 year old man: A case report. AMJ 2013, 6, 12, 694-696. <http://doi.org/10.21767/AMJ.2013.1897>

Corresponding Author:

Yan Herry
Interventionist Cardiologist
Department of Cardiology and Vascular Medicine, Faculty of Medicine Diponegoro University/Dr. Kariadi General Hospital
Jl. Dr. Sutomo no.16, Semarang, Indonesia. 50230.
E-mail: kardio.undip@gmail.com; alvintonang@yahoo.com

Abstract

Spontaneous coronary artery dissection (SCAD), an uncommon cause of myocardial infarction, typically affects a younger, otherwise healthy population. There are currently no known direct causes of this condition, although some correlations have been noted. Commonly found in women, the asymptomatic presentation in men is very rare. Herein, we report the case of an 18-year-old man who presented to our institution with asymptomatic myocardial infarction secondary to a spontaneous dissection of the left anterior descending coronary artery. Until now, there is no specific guideline for SCAD. Choice of treatment should be tailored to the clinical condition of each individual patient.

Key Words

spontaneous coronary artery dissection, myocardial infarction, young age, asymptomatic

Implications for Practice:

1. What is known about this subject?

SCAD is a rare cause of myocardial infarction that is commonly found in women. Generally severe symptoms and sudden cardiac death occurs in SCAD.

2. What is the key finding in this case report?

SCAD can be asymptomatic and may affect men, regardless of age

3. What are the implications for future practice?

SCAD should always be in the differential diagnosis when dealing with unexplained asymptomatic myocardial infarction, regardless of age.

Background

Spontaneous coronary artery disease (SCAD) is a rare and uncommon cause of myocardial infarction. The first reported case in the literature of SCAD appears to be a 42-year old woman with dissection and aneurysm in 1931.¹ Nevertheless, this condition is still not fully understood and the prognosis is associated with sudden cardiac death. We present an unusual case report in an 18-year old adolescent with asymptomatic SCAD.

Case details

A previously healthy and active 18-year old college student underwent a general medical check-up. His past medical history was unremarkable, except a motorcycle accident three years previous that caused multiple facial bone fractures and severe head trauma. He survived the accident with an absence of neurological sequelae or chest discomfort. There were no risk factors for coronary heart disease. His electrocardiogram and echocardiogram consistently showed anterior myocardial infarction (Figure 1 and Figure 2), while the other laboratory parameters were normal. He underwent coronary angiography and showed a dissection in distal LAD artery (Figure 3). Therefore he was diagnosed with recent asymptomatic anterior myocardial infarction caused by spontaneous coronary artery dissection. Further work-up was denied due to the patient and family requests. Indicated medical treatment, including aspirin, beta blocker, and ace inhibitor was given. He was discharged and still active as a college student.

Figure 1: Electrocardiogram of the patient. The electrocardiogram showed right axis deviation, with rS complexes in I, aVL, V1-V5 and T inversion in V2-V5.

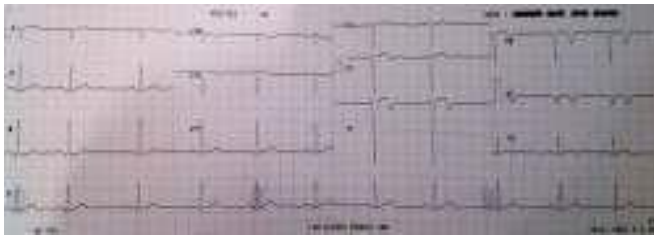


Figure 2: Echocardiogram of the patient. The apical four-chamber-echocardiogram showed apical akinesis, with preserved ejection fraction (white arrow).

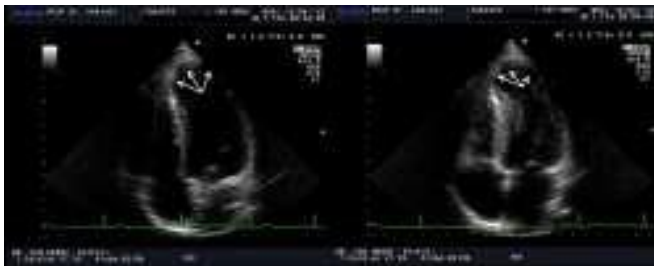
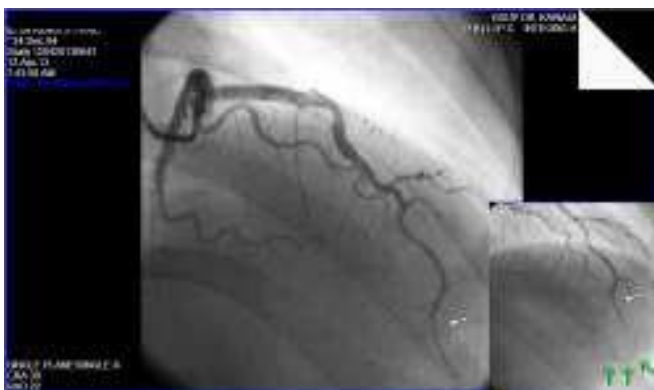
Figure 3: Coronary angiogram of the patient. The coronary angiogram showed dissection in distal left anterior descending (LAD) coronary artery (black arrow), with collateral from diagonal branch to the distal part of the dissection (red arrow). Images obtained from RAO39CRA20 view



Discussion

Spontaneous coronary artery dissection (SCAD) is a rare cause of acute coronary syndrome with devastating prognosis. From about 4000 coronary angiograms consecutively, SCAD was found in 1.1 per cent patients, and commonly found in women rather than men, with a ratio of 2-3:1.^{1,2} Dissection is most commonly found in the left anterior descending (LAD) coronary artery, probably due to the increased shear stress and proximities with the chest, however there are also reports that mention the case of dissection in the left main coronary artery and right coronary artery.² The majority of patients with SCAD has a mean age of approximately 46 years for men and 38 years

for women, and has no risk factors for coronary artery disease.³ Asymptomatic presentation of SCAD is very rare and our search of the literature found only one case report of SCAD in asymptomatic adult men.⁴ The present manuscript reported a SCAD in a very young, 18-year-old patient, suggesting that SCAD should be considered in any age group with unexplained myocardial infarction.

Direct causes of SCAD are still unclear, but it is often associated with connective tissue disorders, Kawasaki disease, atherosclerosis, blunt trauma to the chest wall, systemic lupus erythematosus, excessive exercise, excessive cocaine use, pregnancy, and the postpartum period.^{3,5} In our case, significant history of disease in our case was a motorcycle accident three years ago. Blunt chest trauma can cause various complications in the heart ranging from arrhythmia, rupture of the heart muscle, and heart valves to the rarest complication is coronary artery dissection.⁶ Since our patient was unconscious when the accident happened three years before admission, blunt chest trauma as the main risk factors in our patient could not be ruled out. Injury to the left anterior descending (LAD) coronary artery is the most common site involved due to the proximity of LAD position to the chest wall than the other two blood vessels.⁶ The other cause is denied by the patient, and the connective tissue disorder, such as Marfan's syndrome and type IV Ehler-Danlos syndrome, cannot be ruled out in our case since the patient denied further examination.

Until now there is no specific guideline for SCAD. However, many case reports have demonstrated the efficacy of medical therapy, coronary stents, or even coronary bypass graft surgery.^{2,4} Some cases of SCAD treated using medical therapy were reported successfully. Using antiplatelet, even with GPIIb/IIIa, beta-blocker and some cases with heparin, showed successful and spontaneous closure of the dissection.^{2,4,6} This patient was treated using medical therapy with antiplatelet, beta blocker, and ace inhibitor. Because of the small area involved, as well as the size of the small blood vessels, we chose the medical approach. The patient was then discharged to continue his daily activities. Surely the choice of therapy should be individualised and in accordance with the extent and severity of SCAD.

References

1. Pretty HC. Dissecting aneurysm of coronary artery in a woman aged 42. *BMJ* 1931;1:667.
2. McCann AB, Whitbourn RJ. Spontaneous coronary artery dissection: a review of the etiology and available treatment options. *Heart Vessels*. 2009 Nov;24(6):463-5.
3. Oliveira SM, Gonçalves A, Dias P, Maciel MJ. Spontaneous coronary artery dissection: A diagnosis to consider in acute



coronary syndromes. *Rev Port Cardiol.* 2009;28:707–13.

4. Shankarappa RK, Panneerselvam A, Dwarakaprasad R, Karur S, Krishnanaik GB, Nanjappa MC. Spontaneous asymptomatic coronary artery dissection in a young man. *J Cardiol* 2009;54:499-502.

5. Kalaga RV, Malik A, Thompson PD. Exercise-related spontaneous coronary artery dissection: case report and literature review. *Med Sci Sports Exerc.* 2007 Aug;39(8):1218-20.

6. Yoon SJ, Kwon HM, Kim DS, Hong BK, Kim DY, Cho YH, Kang BS, Kim HS. Acute myocardial infarction caused by coronary artery dissection following blunt chest trauma. *Yonsei Med J.* 2003 Aug 30;44(4):736-9.

ACKNOWLEDGEMENTS

The authors are indebted to all personnel in Dr. Kariadi General Hospital, especially in echocardiography and non-invasive department and the catheterisation laboratory of cardiology and vascular medicine unit Dr. Kariadi General Hospital Semarang.

PEER REVIEW

Not commissioned. Externally peer reviewed.

CONFLICTS OF INTEREST

The authors declare that they have no competing interests.

PATIENT CONSENT

The authors, Yan Herry et al, declare that:

1. They have obtained written, informed consent for the publication of the details relating to the patient(s) in this report.
2. All possible steps have been taken to safeguard the identity of the patient(s).
3. This submission is compliant with the requirements of local research ethics committees.