



Isolated protein S deficiency presenting as catastrophic systemic arterial and subsequently venous thrombosis

Sidhesh B Wagh , Ravi Anadure , Vijay Dutta, M.S.Sandhu, Rahul Trehan

1. Army Base Hospital Delhi Cantonment, New Delhi

CASE REPORT

Please cite this paper as: Wagh S, Anadure R, Dutta V, Sandhu MS, Trehan R, Isolated protein S deficiency presenting as catastrophic systemic arterial and subsequently venous thrombosis. AMJ 2012, 5, 8, 424-428. <http://doi.org/10.21767/AMJ.2012.1309>

Corresponding Author:

Name Dr Siddhesh Wagh

Address: Medical Division, Army Base

Hospital: Delhi Cantonment, New Delhi

Email: drsiddheshwagh@gmail.com

Abstract

Isolated protein S deficiency is an inherited condition having proven association with venous thromboembolism. There is controversy regarding clear association between protein S deficiency and arterial thrombosis. It is therefore necessary to bring focus to this uncommon clinical condition and highlight the probable association with arterial thrombosis facilitating timely diagnosis of this condition. We describe a 48-year-old male with stroke and pulmonary thromboembolism with chronic deep vein thrombosis secondary to isolated protein S deficiency, managed with thrombolysis and long-term anticoagulation.

Key Words

Isolated protein S deficiency; Stroke in young; Pulmonary Thromboembolism; Deep Venous Thrombosis; Thrombolysis.

Implications for Practice

1. This is a rare case of isolated protein S deficiency presenting with catastrophic arterial and venous thrombosis.
2. Isolated protein S deficiency if not recognised early and managed, can lead to catastrophic thrombosis. Thus this case highlights the importance of considering protein S deficiency as a differential in patients with arterial thrombosis.

3. Thrombolytic therapy is the first-line treatment in patients with high-risk pulmonary embolism presenting with cardiogenic shock and/or persistent arterial hypotension.

Background

In 1977, Di Scipio et al in Seattle first purified a new glycoprotein from human plasma which was named protein S, in reference to its isolation and characterisation in Seattle. Protein S is a vitamin K-dependent anticoagulant protein. Its major function is as a cofactor to facilitate the action of activated protein C on its substrates, activated factor V (F Va) and activated factor VIII (F VIIIa). Protein S deficiency usually manifests clinically as venous thromboembolism (VTE)¹⁻³ although few researchers have also reported a relationship between protein S deficiency and arterial thrombosis.⁴⁻⁷

We describe a case with isolated protein S deficiency which experienced both arterial and venous thrombotic events sequentially in spite of being on long-term anti-platelets. Protein S deficiency is a rare cause which is frequently not considered in old patients with strokes on anti-platelets.

Case details

A 48-year-old male living in the plains, was on regular follow-up of two years for a cerebro-vascular accident (left middle cerebral artery infarct) leading to right-sided hemiparesis (Grade IV) and aphasia. The patient was on prophylactic anti-platelets and statins when he presented with complaints of progressive breathlessness on exertion of two months duration. He denied any orthopnoea or paroxysmal nocturnal dyspnea. There was no history of cough, haemoptysis, chest pain, pedal oedema, prolonged immobilisation, angina or syncope. Clinical examination revealed a raised jugular venous pressure, loud pulmonary component of second sound and a grade 3/6 long systolic murmur in the tricuspid area. Electrocardiogram revealed normal sinus rhythm with normal axis. He was referred to cardiology for an urgent 2D Echo which showed a dilated Right Atrium/ Ventricle (RA/RV) with high Right Atrial Pressures (RAP 109 mmHg) and RV wall hypokinesia. A

shortness of breath panel (SOB) showed increased Brain Natriuretic Peptide (BNP) levels 349 IU/L [>100] with normal CPK-MB 1.2 IU/L [0-4.3], Myoglobin 78.4[0-107], Trop I < 0.05 , D- Dimer 2420 [<400].

Figure 1a: CT pulmonary angiography (mediastinal window) showing filling defect in both the pulmonary arteries

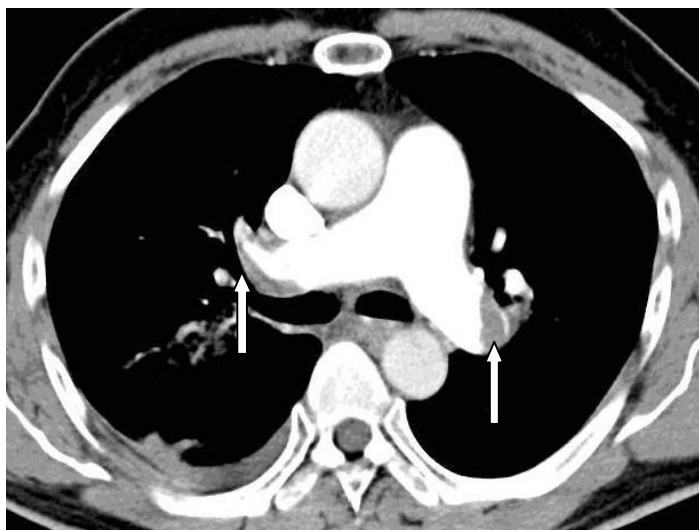
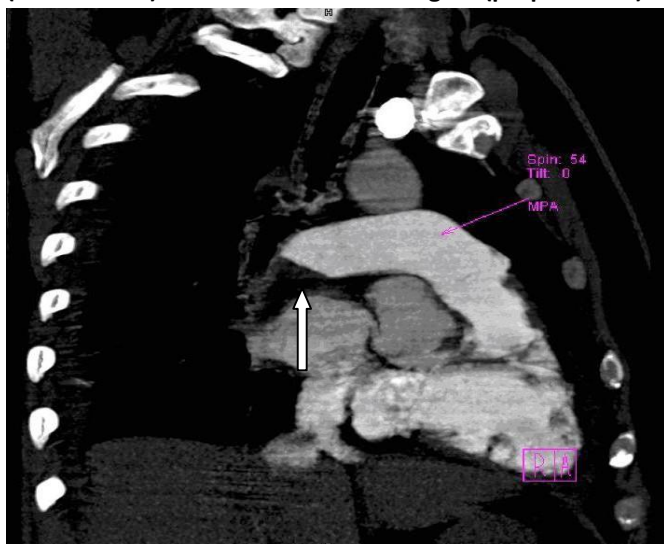


Figure 1b: CT pulmonary angiography reconstruction image showing a filling defect in the right pulmonary artery (white arrow) and the radio contrast agent (purple arrow)



With a high D-Dimer value and a strong clinical suspicion of pulmonary thrombo-embolism, an urgent CT pulmonary angiography was ordered, which showed bilateral thrombosis of pulmonary arteries (Figure 1a) and complete obliteration of the descending branch of right pulmonary artery (Figure 1b), confirming the clinical diagnosis.

Colour Doppler flow imaging of both lower limbs was suggestive of chronic deep venous thrombosis involving the

left popliteal and posterior tibial veins (Organised thrombus).

Investigations

On presentation the lab parameters were as follows:

- haemogram, kidney and liver function tests were within normal limits;
- ultrasonography of abdomen – no evidence of chronic liver disease, spleno portal axis normal;
- Protein C- 72% (70% – 130%);
- Protein S -28% (65% – 140%);
- Anti-thrombin III- 96 (80% – 120%);
- Serum homocystiene levels – Normal;
- Lupus anticoagulant(LA), CD 55/59, Anti-cardiolipin antibodies, HIV Elisa – Negative.

STACLOT protein assay kit was used for analysis of clotting factors.

Treatment

The patient was immediately thrombolysed with Streptokinase 2.5 lakh units after sensitivity testing and 1 lakh units per hour infusion for 24 hours.⁸ No complications were observed during the thrombolysis. The patient was started on Enoxaparin 1mg/ kg (60 mg) bid SC. After seven days of low molecular weight heparin therapy the patient was overlapped with warfarin 5 mg OD and ecosprin 150 mg OD. There was good response to therapy with improvement in dyspnoea and decreased RAP from 109mm of Hg to 34mm of Hg. His INR was 2.3 at discharge.

Outcome and follow-up

The patient became symptomatically better with a decrease in breathlessness from MRC grade III to grade II. There was no change in the motor deficit of the initial stroke, with a residual grade 4 hemiparesis and mild motor aphasia. Follow up 2D Echocardiography showed Right Atrium/Right Ventricle mildly dilated mild Tricuspid Regurgitation with a decrease in RAP from 109 mm of Hg to 34 mm of Hg. The patient was given adequate physiotherapy and deep breathing exercises and has been planned for lifelong anticoagulation with INR in the range of 2-3 with regular follow-up.

Discussion

Congenital protein S deficiency is an autosomal dominant disease, and the heterozygous state occurs in approximately 2% of unselected patients with VTE. Protein S deficiency is rare in a healthy population without abnormalities. The frequency is approximately 1 out of 700 based on extrapolations from a study of over 9000 blood donors who were tested for protein C deficiency. When looking at a selected group of patients with recurrent thrombosis or a



family history of thrombosis, the frequency of protein S deficiency increases to 3-6%.⁹

Very rarely, protein S deficiency occurs as a homozygous state, and these individuals have a characteristic thrombotic disorder, purpura fulminans. Purpura fulminans is characterised by small vessel thrombosis with cutaneous and subcutaneous necrosis, and it appears early in life, usually during the neonatal period or within the first year of life.¹²

During physiological harmony, protein S (cofactor) combines with protein C (serine protease) which then binds to factor Va and VIIIa. Protein S/protein C complex splits factor Va and VIIIa preventing activation of factor X and thrombin, thus preventing thrombosis during the normal state. During deficiency the said mechanism fails, resulting in thrombosis.

In healthy individuals, approximately 30-40% of total protein S is in the free state. Only free protein S is capable of acting as a cofactor in the protein C system. This distinction between free and total protein S levels is important and gives rise to the current terminology regarding the deficiency states.

The congenital deficiencies of protein S are classified in three types:¹⁰⁻¹¹

- type I deficiencies correspond to reduced antigen levels of both total and free protein S;
- type II deficiencies are characterised by reduced protein S activity but with normal antigen levels of both total and free protein S;
- type III deficiencies are defined by a reduced antigen level activity of free protein S but the antigen level of total protein S remains normal.

Acquired protein S deficiencies are associated with several clinical states:

- oral warfarin therapy;
- liver disease;
- disseminated intravascular coagulation;
- oral contraceptives;
- oestrogen therapy;
- acute phase inflammatory responses;
- pregnancy;
- HIV;
- sickle cell disease.

Venous thrombosis develops in 60-80% of patients who are heterozygous for protein S deficiency. The remaining patients are asymptomatic, and some heterozygous individuals never develop VTE. There is controversy

regarding clear association between protein S deficiency and arterial thrombosis. Protein S deficiency is also associated with fetal loss in pregnant women.

Race-related variations exist in thrombophilic disorders as one may expect from genetic-based population traits. There is, a significant difference in the frequency of thrombophilic disorders between white, Japanese (Asian) and black African persons. The protein S deficiency is 5-10 times higher in Japanese populations compared with Caucasians. Protein C deficiency is estimated to be three times higher in Japanese populations. The factor V Leiden mutation is common in white populations. This mutation is rare and almost never found in Japanese or Asian populations. There is no difference between the male-to-female rate of occurrence.

Protein S deficiency is a hereditary disorder, but the age of onset of thrombosis is different in heterozygous or homozygous state. Most venous thrombosis events in heterozygous protein S deficiency occur in persons younger than 40-45 years. The rare homozygous patients have neonatal purpura fulminans, with onset in infancy.

The exact incidence of the protein S deficiency in the Indian population is not known. The association of Protein S deficiency and thromboembolic diseases was reported in several families by Comp, Brokemans, Batard and P K Lieu.¹³

On presentation, the patient had massive venous thrombosis involving the lungs and the leg veins. The duration between onset of symptoms and seeking medical attention was almost two months. Usually, the use of fibrinolytics in the treatment of pulmonary embolism is a controversial topic that has left many practicing physicians confused on how to best treat these patients. A rational approach to deciding whether fibrinolytic therapy is indicated should be based on an assessment of the benefit that each particular patient will derive from fibrinolytic therapy weighed against that patient's risk for major bleeding and intracranial haemorrhage. The success of thrombolytic therapy decreases with the increase in duration from the onset, and only less than 50% success rate is reported after four weeks from the onset. We achieved a good clinical response to the thrombolytic in spite of a long duration of almost eight weeks from the time of onset.

The patient is on regular follow-up with lifelong anticoagulation on warfarin and anti-platelets with monthly monitoring of target INR 2-3. The patient has no evidence of any haemorrhagic manifestations post dual anticoagulation.

The patient has been advised coagulation studies of his siblings and kins.

Figure 2a: Non-contrast CT brain showing left middle cerebral ischaemic infarction

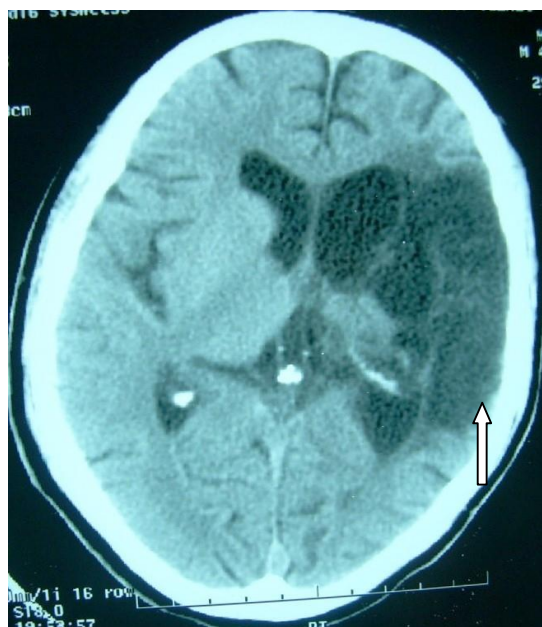
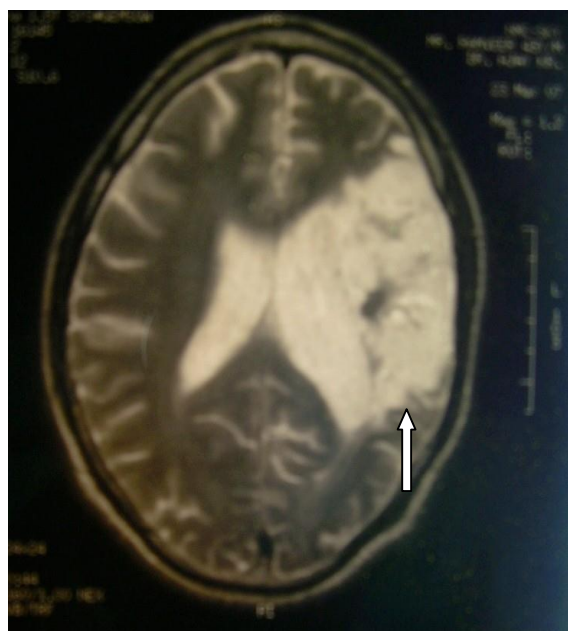
Figure 2b: MRI brain showing left middle cerebral ischaemic infarction



The initial presentation of this case was an arterial ischaemic stroke involving the left middle cerebral artery (Figures 2a and 2b).

Two years later the patient developed massive thrombosis involving the pulmonary arteries and the leg veins in spite of being on anti-platelets. Later the evaluation revealed protein S deficiency. There was no evidence of chronic liver disease, hyperlipidemia, diabetes mellitus or smoking which predispose him for thrombosis. There is no clear association

between protein S deficiency and arterial thrombosis. Ischaemic stroke has been reported as a rare manifestation of protein S deficiency. Girolami et al⁷ and Sie et al¹⁴ first reported the association of familial deficiency of protein S as a cause of ischaemic stroke in young. Wiesel et al¹⁵ studied 105 patients with protein S deficiency, showing relation with arterial events involving central nervous system and the cardiovascular system, while most studies revealed a weaker association between the two.¹⁶⁻¹⁷ Dovay et al¹⁷ reported that hereditary deficiencies of coagulation inhibitors are rare in ischaemic stroke patients under 45 years and their systematic detection seems to be of poor interest. Mayer et al¹⁶ also supported the fact that acquired deficiency of free protein S is not a major risk factor for ischaemic stroke. Lately Hooda et al¹⁸ described a case of recurrent stroke in a 16-year-old female with protein S deficiency. This case highlights a rare presentation and likely association and occurrence of arterial thrombosis in isolated protein S deficiency.

References

1. Schwarz HP, Fischer M, Hopmeier P, Batard MA, Griffin JH. Plasma protein S deficiency in familial thrombotic disease. *Blood* 1984;64:1297-300.
2. Comp PC, Nixon RR, Cooper MR, Esmon CT. Familial protein S deficiency is associated with recurrent thrombosis. *J Clinical Invest* 1984;74:2082-8.
3. Broekmans AW, Bertina RM, Reinalda-Poot J, Engesser L, Muller HP, Leeuw JA, et al. Hereditary protein S deficiency and venous thromboembolism. A study in three dutch families. *Thromb Haemostas* 1985;53:273-7.
4. Coller BS, Owen J, Jesty J, Horowitz D, Reitman MJ, Spear J, et al. Deficiency of plasma protein S, protein C or antithrombin III and arterial thrombosis. *Arteriosclerosis* 1987; 7(5): 456-62.
5. Manucci PM, Tripodi A, Bertina RM. Protein S deficiency associated with "juvenile" arterial and venous thrombosis. *Thromb Haemostas* 1986;55: 440.
6. Israels SJ, Seshia SS. Childhood stroke associated with protein C or S deficiency. *J Pediatr* 1987; 111:562-4.
7. Girolami A, Simioni P, Lassarò AR, Cordiano J. Severe arterial cerebral thrombosis in a patient with protein S deficiency (moderately reduced total and markedly reduced free protein S): A family study. *Thromb Haemostas* 1989;61:144-7.
8. Guidelines on the diagnosis and management of acute pulmonary embolism. European Society of Cardiology --- Medical Specialty Society. 2000 Aug (revised 2008 Sep). 40 pages. NGC:006821
9. Brouwer JL, Lijfering WM, Ten Kate MK, Kluin-Nelemans HC, Veeger NJ, van der Meer J. High long-term absolute risk



of recurrent venous thromboembolism in patients with hereditary deficiencies of protein S, protein C or antithrombin. *Thromb Haemost.* Jan 2009;101(1):93-9.

10. Lane DA, Mannucci PM, Bauer KA, Bertina RM, Bochkov NP, Boulyjenkov V, et al. Inherited thrombophilia: Part 1. *Hemostasis* 1996;76: 651-662..

11. The 1991 meeting of the Scientific Subcommittee of the International Society on Thrombosis and Haemostasis in Munich, Germany

12. Edlich RF, Cross CL, Dahlstrom JJ, Long WB 3rd. Modern concepts of the diagnosis and treatment of purpura fulminans. *J Environ Pathol Toxicol Oncol.* 2008;27(3):191-6.

13. Lieu PK, Lee SH, Tan CB, Tan ES. Recurrent cerebral thrombosis associated with Protein S deficiency in a Chinese female. *Singapore Med J* 1992;33:418-19.

14. Sie P, Boneu B, Bierme R, Wiesel ML, Grunebaum L, Cazenave JP. Arterial thrombosis and protein S deficiency. *Thromb Haemost.* 1989; 62:1040.

15. Wiesel ML, Borg JY, Grunebaum L, Vasse M, Levesque H, Bierme R, Sie P. Influence of protein S deficiency on the arterial thrombosis risk. *Presse Med.* 1991; 20:1023-7.

16. Mayer SA, Sacco RL, Hurler-Jensen A, Shi T, Mohr JP. Free protein S deficiency in acute ischemic stroke. A case-control study. *Stroke.* 1993; 24:224-7.

17. Dovay X, Lucas C, Caron C Goudemand J, Leys D. Antithrombin, protein C and protein S in 127 consecutive young adults with ischemic stroke. *Acta Neurol Scand.* 1998; 98:124-7.

18. Amit Hooda, P. D. Khandelwal, and Puneet Saxena. Protein S deficiency: Recurrent ischemic stroke in young. *Ann Indian Acad Neurol.* 2009; 12(3): 183-184.

2. All possible steps have been taken to safeguard the identity of the patient(s).
3. This submission is compliant with the requirements of local research ethics committees.

ACKNOWLEDGEMENTS

We thank the Department of Radiology, Base Hospital for providing us with the CT Reconstruction imaging.

PEER REVIEW

Not commissioned. Externally peer reviewed.

CONFLICTS OF INTEREST

The authors declare that they have no competing interests

FUNDING

None

PATIENT CONSENT

The authors, Wagh S, Anadure R, Dutta V, Sandhu MS, Trehan R, declare that:

1. They have obtained written, informed consent for the publication of the details relating to the patient(s) in this report.