



# Two cases of bilateral ischemic optic neuropathy following coronary artery bypass grafting

M Ashok Kumar, Krishnagopal Srikanth

Department of Ophthalmology, Mahatma Gandhi Medical College and Research Institute, Puducherry, India

## CASE REPORT

Please cite this paper as: Kumar MA, Srikanth K. Two cases of bilateral ischemic optic neuropathy following coronary artery bypass grafting. AMJ 2012, 5, 7, 352-354. <http://doi.org/10.21767/AMJ.2012.1245>

### Corresponding Author:

Dr.M.Ashok Kumar  
Professor, Dept. of ophthalmology,  
Mahatma Gandhi Medical College and Research  
Institute, Pillayarkupam, Puducherry, India  
607402  
Email: [drmashok74@rediffmail.com](mailto:drmashok74@rediffmail.com)

## Abstract

Postoperative vision loss (POVL) after major non-ocular surgery is a very rare but devastating complication since it has the potential to cause bilateral, severe and permanent loss of vision. The common major procedures resulting in POVL are cardiac and spinal procedures. We are reporting two patients who presented with features of bilateral anterior ischaemic optic neuropathy after coronary artery bypass grafting.

### Key Words

Coronary artery bypass grafting, postoperative visual loss, ischemic optic neuropathy

## Implications for Practice

1. POVL following Coronary Artery Bypass Grafting (CABG) is a very rare entity with the pathogenesis not well known.
2. POVL occurred due to ischemic optic neuropathy in two patients following CABG and was associated with risk factors such as hypertension, dyslipidemia, anaemia and carotid atherosclerotic plaque.

3. Awareness of this very rare but devastating cause of bilateral severe visual loss after major non-ocular surgery such as CABG and spinal procedures is a must for the treating team.

## Background

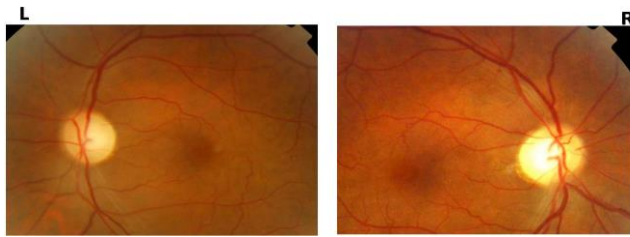
Post operative vision loss (POVL) after surgery unrelated to the orbit is a very rare but devastating complication following major surgical procedures. The highest rate of POVL is reported after cardiac and spine surgeries.<sup>1</sup> The major cause of POVL is ischaemic optic neuropathy (ION).<sup>2</sup> We are reporting two cases of ION immediately following coronary artery bypass grafting (CABG) who presented to us a few weeks after the onset of POVL.

## Case details

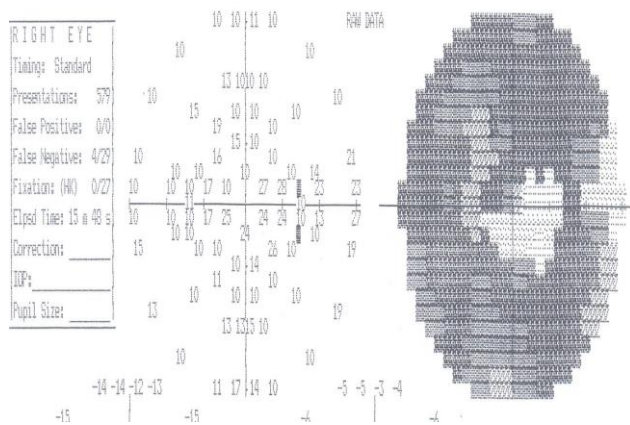
### Case report 1

A 52-year-old non-diabetic male who was on treatment for hypertension and dyslipidemia for 10 years' duration underwent CABG for left main coronary artery stenosis diagnosed by coronary angiography performed one week before CABG. Postoperatively he gave history of regaining consciousness after three days and noticed bilateral grossly diminished vision. He reported to us two months after the episode having received treatment elsewhere for the same condition. On evaluation he had visual acuity of 20/200 in the right eye and 20/400 in the left eye with bilateral afferent pupillary defect. Bilateral disc pallor with blurring of disc margins was noted (Figure 1). Visual fields showed constricted visual field in the right eye (Figure 2). A review of his past records showed pre-operative and post-operative haemoglobin concentration of 8.2 gm/dl and 7.8 gm/dl respectively. Pre and post-operative blood sugar, blood pressure and lipid profile were within normal limits. Colour doppler imaging of the carotids was normal. No records regarding use of cardiopulmonary bypass (CPB), intraoperative blood loss and hypotension were available with the patient.

**Figure 1: Bilateral pallor of the optic disc with mild blurring of disc margins**



**Figure 2: Automated perimetry by 30-2 fast threshold strategy shows constricted visual field in the right eye**



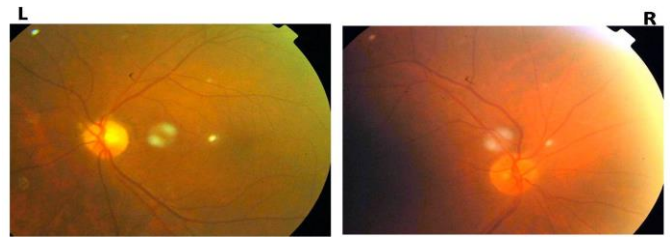
Over six months follow-up his visual acuity was stable at 20/200 in the right eye and 20/400 in the left eye.

### Case report 2

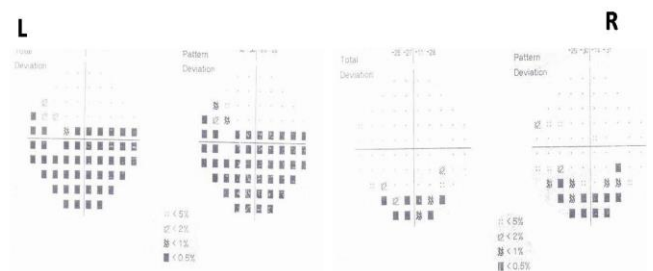
This report is about a 70-year-old male who underwent CABG with CBP for three-vessel disease diagnosed by coronary angiography done two weeks before CABG. He was on treatment for diabetes mellitus and systemic hypertension for 20 years and 10 years respectively. After recovering from anaesthesia the patient noticed blurred vision in the left eye. He presented to us one month after the episode with visual acuity of 20/40 in the right eye and 20/400 in left eye. He had bilateral nuclear cataract with relative afferent pupillary defect in the left eye. Fundus examination showed pallor of the superior pole of the disc in both eyes, more in the left eye, with mild blurring of superior disc margin (Figure 3). Visual fields showed altitudinal field defect involving fixation in the left eye and inferior arcuate field defect in the right eye (Figure 4). Pre and post-operative haemoglobin concentration, blood sugar, lipid profile and blood pressure were within normal limits. Available records showed no details regarding intraoperative blood loss and hypotension.

Carotid doppler imaging performed by us showed atherosclerotic stenosis of both internal carotid arteries (Figure 5).

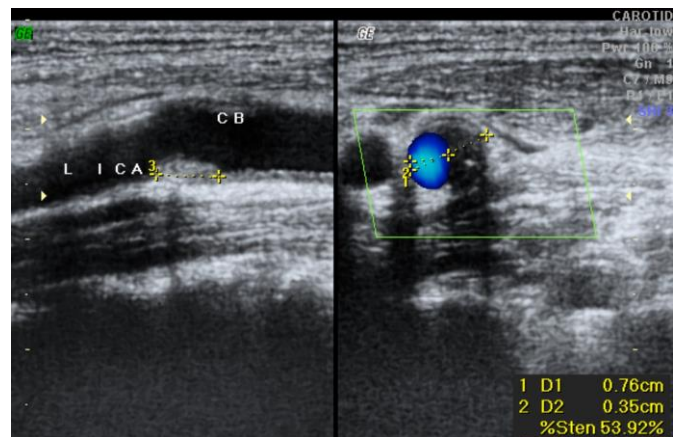
**Figure 3: Bilateral pallor of the optic disc (Left more pale than the right) with blurring of superior margins of the disc**



**Figure 4: Automated perimetry showing inferior altitudinal field defect involving fixation in left eye and inferior arcuate scotoma in right eye**



**Figure 5: Carotid doppler imaging showing atherosclerotic plaque causing upto 53.92% stenosis of left internal carotid artery**



### Discussion

The reported incidence of ION after CABG is from 0.06% to 1.3%.<sup>3,4</sup> Also the incidence of POVL after CABG has shown an increase over the years. This is possibly due to the heightened awareness of this complication.<sup>5</sup> ION can be anterior ischemic optic neuropathy (AION) or posterior ischemic optic neuropathy (PION). Johnson et al suggested three sites of ischaemia leading to POVL; occipital cortex, juxtalamina optic nerve supplied by short posterior ciliary arteries (causing AION) and orbital optic nerve supplied by pial capillary plexus (causing PION).<sup>6</sup> AION typically presents with diminished vision, field defects and swollen optic disc which atrophies over a month. PION presents with a normal



disc initially which atrophies later. In the cases being reported by us both had features suggestive of AION though the second patient had only an arcuate field defect without significant loss of vision in the right eye.

The risk factors for ION after CABG include prolonged CPB, lower haematocrit, high dose of inotropic drugs, hypotension and large volume of fluid infusions.<sup>4</sup> Nuttall et al showed preoperative coronary angiography 48 hours before CABG, postoperative Hb concentration of < 8.5 gm/dl and atherosclerotic vascular disease as significant risk factors but diabetes mellitus and smoking were not significantly associated with POVL.<sup>3</sup> Mansour et al showed that severe anaemia in diabetics undergoing CABG had a significant risk of developing ION and reversal of anaemia in the patients could salvage the vision.<sup>7</sup> CPB itself can induce shower of thromboemboli affecting the optic nerve perfusion and Kalyani et al showed an absence of any case of PION in their series where cardiac surgery was performed without CPB.<sup>8,9</sup> But Holy et al found no significant haemodynamic factors in the perioperative period in patients with PION following major surgical procedures.<sup>10</sup>

In the cases reported by us the patients had risk factors for atherosclerotic vascular disease like hypertension and dyslipidemia (case 1 & 2), CPB (case 2), anaemia with haemoglobin concentration of < 8.5gm/dl (case 1) and carotid atherosclerotic plaque with stenosis (case 2).

The cause of ION after major surgeries including CABG is multifactorial and varies from patient to patient.<sup>2</sup> But the optic nerve is the most susceptible to vulnerable watershed zone as shown by Shapira et al since none of the patients in their series with ION (n=8) had cerebrovascular accident or myocardial infarction.<sup>4</sup> Altering any haemodynamic parameter to avoid this very rare complication of major surgery may be more harmful than beneficial. Also there is no proven effective treatment once the ION has set in.<sup>2</sup>

These two cases are being reported because of the rarity of occurrence and the implications of severe visual loss in a patient undergoing non-ocular surgery. Lack of valuable perioperative data prevented us from evaluating for various other significant risk factors in these patients. Also a literature search regarding postoperative visual loss after CABG did not reveal any major series from India. Evaluation of POVL after CABG in centres with high volume CABG procedures can help to identify the risk factors as well as the magnitude in Indian scenario and help in understanding further about this rare manifestation.

## References

1. Roth S. Postoperative blindness, Anesthesia, 6th edition. Edited by Miller RD. New York, Elsevier/Churchill Livingstone 2005, pp 2991–3020.
2. Newman NJ. Perioperative visual loss after nonocular surgeries. *Am. J. Ophthalmol* 2008;145:604–10.
3. Nuttall GA, Garrity JA, Dearani JA, Abel MD, Schroeder DR, Mullany CJ. Risk factors for ischemic optic neuropathy after cardiopulmonary bypass: A matched case/control study. *Anesth Analg* 2001; 93:1410–6.
4. Shapira OM, Kimmel WA, Lindsey PS, Shahian DM. Anterior ischemic optic neuropathy after open heart operations. *Ann Thorac Surg* 1996; 61:660–6.
5. Remigio D, Wertenbaker C. Post-operative bilateral vision loss. *Surv Ophthalmol* 2000;44:426–32.
6. Johnson MW, Kincaid MC, Trobe JD. Bilateral retrobulbar optic nerve infarctions after blood loss and hypotension. A clinicopathologic case study. *Ophthalmology* 1987;94:1577–84.
7. Mansour AM, Awwad ST, Najjar DM, Sibai AN, Sibai AM, Medawar WA et al. Anterior ischaemic optic neuropathy after coronary artery bypass graft: the role of anaemia in diabetics. *Eye (Lond)*. 2006;20:706–11.
8. Blauth CI, Smith PL, Arnold JV, Jagoe JR, Wootton R, Taylor KM. Influence of oxygenator type on the prevalence and extent of microembolic retinal ischemia during cardiopulmonary bypass. Assessment by digital image analysis. *J Thorac Cardiovasc Surg* 1990;99:61–9.
9. Kalyani SD, Miller NR, Dong LM, Baumgartner WA, Alejo DE, Gilbert TB. Incidence of and risk factors for perioperative optic neuropathy after cardiac surgery. *Ann Thorac Surg* 2004;78:34–7.
10. Holy SE, Tsai JH, McAllister RK, Smith KH. Perioperative ischemic optic neuropathy: a case control analysis of 126,666 surgical procedures at a single institution. *Anesthesiology* 2009;110:246–53.

## CONFLICTS OF INTEREST

The authors declare that they have no competing interests.

## PATIENT CONSENT

The authors, M Ashok Kumar, Krishnagopal Srikanth, declare that:

1. They have obtained written, informed consent for the publication of the details relating to the patient(s) in this report.
2. All possible steps have been taken to safeguard the identity of the patient(s).
3. This submission is compliant with the requirements of local research ethics committees.