



## Left ventricular thrombus in patients with acute myocardial infarction:

### Case report and Caribbean focused update

CR Potu<sup>1,2</sup>, EE Tulloch-Reid<sup>1,2</sup>, DS Baugh<sup>1,2</sup>, EC Madu<sup>1,2</sup>

1. Department of Medicine, Division of Cardiovascular Medicine, Heart Institute of the Caribbean, Kingston, Jamaica

2. Center of Excellence for Cardiovascular Medicine and Sports Physiology, University of Technology, Kingston, Jamaica.

#### CASE REPORT

Please cite this paper as: CR Potu, EE Tulloch-Reid, DS Baugh, EC Madu. Left ventricular thrombus in patients with acute myocardial infarction. A case report and Caribbean focused update. AMJ 2012, 5, 3, 178-183. <http://doi.org/10.21767/AMJ.2012.1103>

#### Corresponding Author:

Ernest C. Madu, MD, FACC, FRCP (Edin).  
Division of Cardiovascular Medicine  
Heart Institute of the Caribbean  
23 Balmoral Avenue, Kingston 10, Jamaica\_  
[Email: emadu@caribbeanheart.com](mailto:emadu@caribbeanheart.com)

#### Abstract

Despite the well documented benefit of echocardiography in acute coronary syndromes, its wide-scale use in the Caribbean is limited by access, health literacy and affordability. Because of the limited use of echocardiography in the region, routine complications of acute myocardial infarction (AMI) are not fully appreciated and may go unrecognized, further contributing to increased cardiovascular morbidity and mortality. It is therefore necessary to bring focus to this common clinical condition and highlight the clinical utility of echocardiography in facilitating timely and accurate diagnosis. We report here a case of large left ventricular (LV) thrombus in a patient with AMI. Coronary angiography showed completely occluded left anterior descending artery (LAD) with angiographically normal remaining vessels. Immediate anticoagulation was commenced with heparin and overlapped with warfarin. No Primary Angioplasty (PA) was done based on the evidence from occluded artery trial. LV thrombus was completely resolved on echocardiography at three months. No evidence of thrombo-embolism was found during the resolution of LV thrombus.

#### Key Words

Myocardial infarction, LV thrombus, Echocardiography, Anticoagulation

#### Background

LV thrombus is a well recognized complication of AMI. It is estimated that 40-60% of patients with large anterior wall MI will develop a LV thrombus.<sup>1,2</sup> Accurate and timely detection is important as it poses a high risk for thromboembolic events<sup>3,4</sup> which can be prevented by systemic anticoagulation.<sup>5,6</sup> Two-dimensional echocardiography has played a pivotal role in defining the natural history of thrombus formation in post MI patients. Risk factors for the development of LV thrombus include age, infarct location, infarct number, size and extent, and impairment in global or regional LV function (i.e. ejection fraction <40%). It occurs most commonly in anterior wall MI compared to non-anterior wall MI.<sup>7</sup> We report here a case of large LV thrombus in a 61-year-old male with extensive anterior wall MI describing the diagnosis, therapeutic options, prognosis, and the practical strategies to prevent embolic complications.

#### Case details

A 61-year-old male patient with multiple risk factors for coronary artery disease was referred to our facility for echocardiography, three days after his admission to local public hospital for retrosternal chest pain. Even though the patient presented at the local public hospital within two hours of symptom onset and was at the time of presentation diagnosed (by 12 lead electrocardiogram and cardiac enzyme assay) with acute extensive anterior wall MI, thrombolytic therapy (TT) was not given and the patient was not referred for percutaneous intervention because these services were not available at the local public hospital. In addition, entrenched local practice patterns favored a conservative approach despite evidence to the contrary. Attempted transfer to an affiliated tertiary university hospital was unsuccessful due to bureaucratic and structural bottlenecks further delaying appropriate care with increasing morbidity and mortality risk for the patient. The patient was only transferred to our private facility after three days of delayed diagnostic testing and treatment. An echocardiogram was performed at our facility which demonstrated dilated LV with severely reduced systolic

function with an ejection fraction (EF) of 30-35%. Important regional wall motion abnormalities were present with akinesis of anteroseptal wall and LV apex, and severe hypokinesis of the lateral wall. Both findings were consistent with a recent extensive anterior wall MI. A large fresh apical thrombus was noted (Figure 1a) with spontaneous echo contrast, providing further evidence of low flow state. Coronary angiography (Figure 2) was recommended and performed on the same day which demonstrated complete occlusion of LAD at its origin but angiographically normal left main (LM), left circumflex (LCX) and dominant right coronary arteries (RCA) without any significant collateral circulation. The patient was then admitted to a private hospital and anticoagulation was initiated with low molecular weight heparin with a subcutaneous enoxaparin at a dose of 2mg/Kg given twice daily. Oral warfarin was started and antiplatelet agents were continued. A repeat echocardiogram was performed prior to discharge after seven days of overlap which confirmed a resolving thrombus and no evidence of new thrombus formation. He was discharged after we were satisfied that the repeated international normalised ratio (INR) values were within the therapeutic range (2-3). Dual antiplatelet therapy was also continued and his INR was carefully monitored as an outpatient. Repeat echocardiograms were performed at the follow-up visits at six weeks (Figure 1b) and three months (Figure 1c) after discharge. These showed complete resolution of the large apical thrombus at three months with no evidence of new thrombus formation. Warfarin therapy was continued for six months and then stopped.

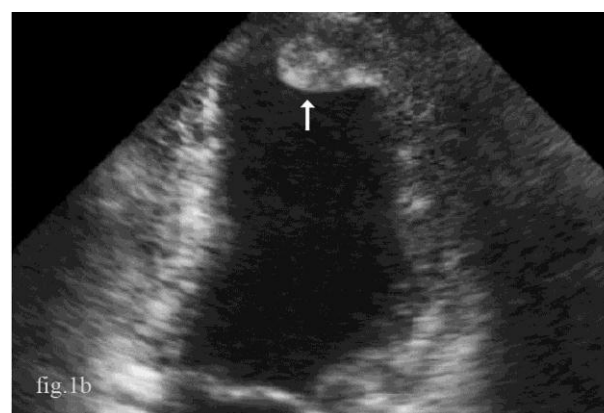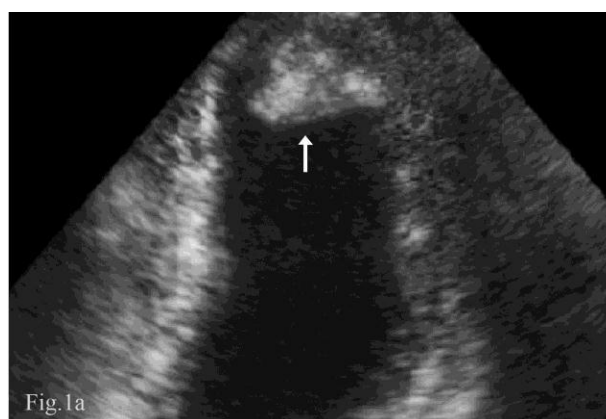## Discussion

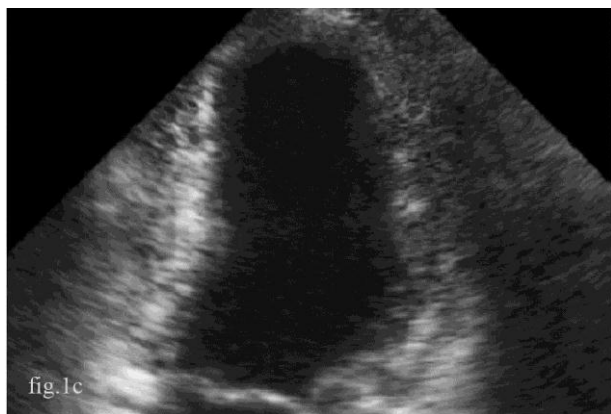LV thrombus is a serious complication of AMI, with most thrombi developing during the first two weeks (median five to six days) after the initial AMI.<sup>3</sup> In patients with extensive anterior wall MI, the development of thrombus may start as early as a few hours after MI evolving in to full blown thrombus by the third to fifth day. LV thrombus was diagnosed in our patient when the initial echocardiogram was undertaken (three days after presentation) and we are therefore uncertain as to when the thrombus first developed – it is possible that it was formed within the first 24 hours given the extensive transmural myocardial injury. While many patients will develop thrombi while still hospitalised, it has been reported that patients with AMI may develop a new thrombus after the hospital discharge especially in patients with severe LV dysfunction<sup>8</sup> and hence serial echocardiograms should be considered in such patients. The incidence of LV thrombus in the current era of reperfusion therapy is variable. Several studies have reported the decreased incidence of LV thrombus in

patients treated with either TT9<sup>9,10</sup>, or PA<sup>11,12</sup> compared to those who did not receive reperfusion therapy. Vaitkus et al<sup>5</sup> in a meta-analysis have reported the reduction in the incidence LV thrombus with TT, which however did not achieve statistical significance. Osherov et al,<sup>13</sup> in a recent study compared the incidence of LV thrombus in patients treated with PA, TT and conservative therapy respectively, and reported that in the current era of rapid reperfusion by PA, the rate of thrombus formation is similar to that reported in the past and no difference was noted compared to those treated with either conservatively or thrombolysis.

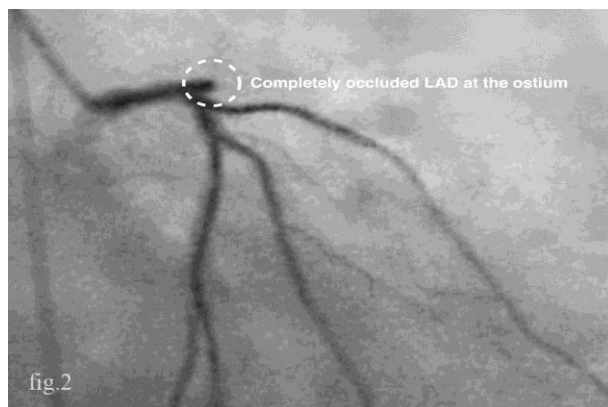
Two-dimensional non-contrast transthoracic echocardiography (TTE) is the most commonly used technique for the clinical identification and follow-up of LV thrombi based on anatomical appearance. It has sensitivity and a specificity of 92–95% and 86–88% respectively for the diagnosis of LV thrombs.<sup>14,15</sup>

**Figures 1a-c: Echocardiogram showing the size of LV thrombus at third day, sixth week and end of third month after AMI. Arrows indicate LV thrombus.**





**Figure 2: Angiogram (day 3) showing the completely occluded LAD at the ostium**



Despite the high accuracy it can be technically difficult in some patients because of the difficulty in discerning the myocardium-thrombus interface, limited near field resolution of the apex, or difficulty in obtaining images of the true apex. Recent studies have reported that up to two-thirds of LV thrombi can be missed by routine non-contrast echo, with mural or small thrombi least likely to be detected.<sup>16-18</sup> Application of advanced echocardiographic techniques such as harmonic imaging and contrast echocardiography improves the diagnostic detection by improving the LV endocardial border definition, cavity delineation, and overall image quality and can be recommended.<sup>19,20</sup> Recent advances in cardiac imaging have enabled assessment of vascular supply, allowing thrombi to be identified by avascular tissue characteristics rather than anatomical criteria resulting from absence of contrast uptake. Magnetic resonance imaging (MRI) with contrast enhancement has shown promise in the identification of LV thrombus, having greater sensitivity and specificity than TTE and trans-esophageal echocardiography (TEE).<sup>16</sup> In particular, the delayed contrast-enhanced MRI technique using an inversion recovery pulse to suppress signal of normal myocardium has been shown to be highly beneficial in detecting intracavitary thrombi (which are dark), in addition to being an excellent technique for depicting adjacent MI and scarring. Weinsoft et al<sup>17</sup> in a comparison

study involving 121 patients using delayed contrast-enhanced MRI as a reference standard for detection of LV thrombus reported sensitivities of 33%, 61%, and 79% for echo, contrast echo and cine-CMR respectively.

LV thrombus increases the risk for embolic complications. The reported frequency of occurrence of stroke in patients with AMI is 1.5% to 3.6% which is thought to be embolic from a mural thrombus.<sup>5</sup> Characteristics of thrombi that are associated with high risk for embolisation include mobility, protuberance, immaturity, filamentous nature, variable echo density with central liquefaction and irregular borders. Studies have shown that 55 % of mobile thrombi and 45% of protruding thrombi embolize compared to 10% immobile and 7% non-protruding thrombi<sup>21,22</sup> respectively.

In patients with LV thrombus or severe LV dysfunction complicating a recent MI, aggressive anti-thrombotic therapy with unfractionated or low molecular heparin should be immediately started and long term overlapped with warfarin. High dose intravenous heparin therapy<sup>23</sup> with or without warfarin has been shown to be associated with reduction in the rate of thrombus formation and embolic phenomena during acute MI. Vaitkus et al.<sup>5</sup> in a meta-analysis have shown that the administration of anticoagulation is associated with significant reduction in embolic events. ACC/AHA gave a class I recommendation that intravenous unfractionated heparin or low molecular weight heparin should be used in patients after ST-elevation MI who are at high risk for systemic emboli (occurrence of a large anterior infarction, documentation of thrombus in the LV by echocardiography, history of a previous embolic event, and atrial fibrillation).<sup>24</sup> Treatment with warfarin without concomitant high dose heparin has been associated with high prevalence of LV thrombus and embolic complications. Kontny et al.,<sup>25</sup> in a study involving 229 patients, reported an increased prevalence of LV thrombus formation in patients treated with warfarin without concomitant high-dose heparin therapy and a similar but non-significant difference was observed in patients who were given low-dose heparin. The ability of warfarin to reduce the coagulation inhibitors (protein C and S) faster than the coagulation factors (Prothrombin-II) may result in a transient hypercoagulable state at the beginning of the therapy<sup>26,27</sup> and hence it should ideally be overlapped with heparin to prevent thromboembolic complications. Once the therapeutic INR is reached heparin can be discontinued and oral anticoagulation continued for at least three to six months or indefinitely. Antiplatelet therapy has not been shown to be associated with reduced incidence of embolic complications.<sup>5</sup>



The recommendation of TT for the treatment of LV thrombus is controversial. Available data is conflicting with a number of studies showing their beneficial effect<sup>9,10</sup> and a number of other studies<sup>28,29</sup> showing the contrary. Choice of thrombolytic agent did not have any impact on the LV thrombus formation.<sup>30</sup> Moreover, TT can cause increased mobility of apical thrombus resulting in an increased tendency towards embolisation.<sup>31</sup> Overall, no consensus has been achieved regarding the efficacy of TT for the treatment of LV thrombus. Thrombolysis or PA is undertaken with the primary goal of achieving coronary artery patency, which would be expected to prevent mural thrombi by preserving the viability of myocardium and preventing wall motion abnormalities. No TT was given during this patient's stay in the local public hospital due to non-availability. The interventional cardiologists at the Heart Institute of the Caribbean (HIC) collectively made a decision not to attempt PA of the occluded infarct-related artery based on the evidence from occluded artery trial (OAT).<sup>32</sup> According to the OAT, late opening of the occluded infarct related artery (3–28 days after AMI) with percutaneous coronary intervention was not associated with any improved clinical end points (reduced occurrence of death, re-infarction or heart failure) and there was a trend toward excess re-infarction during a four-year follow-up period and hence it was not recommended in our patient. Repeat echocardiograms were done at six weeks and three months with the three-month study showing complete resolution of the thrombus. Although there is no consensus regarding the time intervals to perform the serial echocardiograms to avoid missing the diagnosis of late occurring LV thrombus, clinical judgment and consideration of other factors such as severity of AMI and LV dysfunction can be used to make the recommendation.

In summary LV thrombus should be suspected in patients with large anterior wall MI. If not recognised and treated immediately, it can result in life-threatening embolic complications. Echocardiogram is a simple, inexpensive and non-invasive technique that is crucial for immediate diagnosis. Effective measures should be taken by the various stakeholders to provide this necessary service in public hospitals or forge a meaningful partnership with better equipped private sector healthcare providers to make these services accessible to the population in a timely manner, thereby ensuring that patients receive evidence-based medicine that takes advantage of advances in medical knowledge and technology. This will facilitate a reduction in the social and economic burden of cardiovascular disease and mortality associated with the disease.

## References

1. Kupper AJ, Verheugt FW, Peels CH, Galema TW, Roos JP. Left ventricular thrombus incidence and behavior studied by serial two-dimensional echocardiography in acute anterior myocardial infarction: left ventricular wall motion, systemic embolism and oral anticoagulation. *J Am Coll Cardiol* 1989, 13:1514-1520.
2. Stokman PJ, Nandra CS, Asinger RW. Left ventricular thrombus. *Curr Treat Option Cardiovasc Med* 2001, 3:515-521.
3. Greaves SC, Zhi G, Lee RT, Solomon SD, Macfadyen J, Rapaport E, Menapace FJ, Rouleau JL, Pfeffer MA. Incidence and natural history of left ventricular thrombus following anterior wall acute myocardial infarction. *Am J Cardiol* 1997, 80:442-8.
4. Kontny F, Dale J, Nesvold A, Lem P, Soberg T. Left ventricular thrombosis and arterial embolism in acute anterior myocardial infarction. *J Intern Med* 1993, 233:139-43.
5. Vaitkus PT, Barnathan ES. Embolic potential, prevention and management of mural thrombus complicating anterior myocardial infarction: a meta-analysis. *J Am Coll Cardiol* 1993, 22:1004-9.
6. Kontny F, Dale J, Abildgaard U, Pedersen TR. Randomized trial of low molecular weight heparin (dalteparin) in prevention of left ventricular thrombus formation and arterial embolism after acute anterior myocardial infarction: the Fragmin in Acute Myocardial Infarction (FRAMI) Study. *J Am Coll Cardiol* 1997, 30:962-9.
7. Van Dantzig JM, Delemarre BJ, Bot H, Visser CA. Left ventricular thrombus in acute myocardial infarction. *Eur Heart J*, 1996, 17:1640-1645.
8. Moe T, Tein D, Karp K, Eriksson P. Long-term follow-up of patients with anterior myocardial infarction complicated by left ventricular thrombus in the thrombolytic era. *Heart* 1996, 75:252-6.
9. Eigler N, Murer G, Shah PK. Effect of early systemic thrombolytic therapy on left ventricular mural thrombus formation in acute anterior myocardial infarction. *Am J Cardiol* 1984, 54:261-263.
10. Porter A, Kandalkar H, Iakobishvili Z, Sagie A, Lmbar S, Battler A, Hasdai D. Left ventricular mural thrombus after acute myocardial infarction in the era of aggressive reperfusion therapy – still a frequent complication. *Coron Artery Dis* 2005, 16:275-279.
11. Rehan A, Kanwar M, Rosman H, Ahmed S, Ali A, Gardin J, Cohen G. Incidence of post myocardial infarction left thrombus formation in the era of primary percutaneous intervention and glycoprotein IIb/IIIa inhibitors. A prospective observational study. *Cardiovasc Ultrasound* 2006, 4:20.



12. Solheim S, Seljeflot I, Lunde K, Bjornerheim R, Aakhus S, Forfang K, Arnesen H. frequency of left ventricular thrombus in Patients with anterior wall acute myocardial infarction treated with percutaneous coronary intervention and dual anti platelet therapy. *Am J Cardiol* 2010, 106: 1197-1200.
13. Osherov AB, Borovik-Raz M, Aronson D, Agmon Y, Kapeliovich M, Kerner A, Grenadier E, Hammerman H, Nikolsky E, Roguin A. Incidence of early left ventricular thrombus after acute anterior wall myocardial infarction in the primary coronary intervention era. *Am Heart J* 2009, 157:1074-1080.
14. Stratton JR, Lighty Jr GW, Pearlman AS, Ritchie JL. Detection of left Ventricular thrombus by two-dimensional Echocardiography: sensitivity, and causes of uncertainty. *Circulation* 1982, 66:156 - 66.
15. Visser CA, Kan G, David GK, Lie KI, Durrer D. Two dimensional echocardiography in the diagnosis of left ventricular thrombus. A prospective study of 67 patients with anatomic validation. *Chest* 1983, 83: 228-32.
16. Srichai MB, Junor C, Rodriguez LL, Stillman AE, Grimm RA, Lieber ML, et al. Clinical, imaging, and pathological characteristics of left ventricular thrombus: a comparison of contrast-enhanced magnetic resonance imaging, transthoracic echocardiography, and transesophageal echocardiography with surgical or pathological validation, *Am Heart J*, 2006, 152:75-84.
17. Weinsaft JW, Kim RJ, Ross M, Krauser D, Manoushagian S, LaBounty TM, Cham MD, Min JK, Healy K, Wang Y, Parker M, Roman MJ, Devereux RB. Contrast enhanced anatomic imaging as compared to contrast-enhanced tissue characterization for detection of left ventricular thrombus. *J Am Coll Cardiol Img*, 2009, 2:969-79.
18. Thanigaraj S, Schechtman KB, Perez JE. Improved echocardiographic delineation of left ventricular thrombus with the use of intravenous second-generation contrast image enhancement. *J Am Soc Echocardiogr* 1999, 12:1022-1026.
19. Mulvagh SL, Rakowski H, Vannan MA, Abdelmoneim SS, Becher H, Bierig SM, Burns PN, Castello R, Coon PD, Hagen ME, Jollis JG, Kimball TR, Kitzman DW, Kronzon I, Labovitz AJ, Lang RM, Mathew J, Moir WS, Nagueh SF, Pearlman AS, Perez JE, Porter TR, Rosenbloom J, Strachan GM, Thanigaraj S, Wei K, Woo A, Yu EHC, Zoghbi WA. American Society of Echocardiography Consensus Statement on the Clinical Applications of Ultrasonic Contrast Agents in Echocardiography. *J Am Soc Echocardiogr*, 2008, 21:1179-1201.
20. Mansencal N, Nasr IA, Pilliere R, Farcot JC, Joseph T, Lacombe P, Dabourg O. Usefulness of contrast echocardiography for assessment of left ventricular thrombus after acute myocardial infarction. *Am J Cardiol*, 2007, 99:1667-70.
21. Johannessen K-A, Nordrehaug JE, Von der Lippe G, Vollset SE. Risk factors for embolisation in patients with left ventricular thrombi and acute myocardial infarction. *Br Heart J* 1988, 60:104-10.
22. Jugdutt BI, Sivaram CA, Wortman C, Trudell C, Penner P. Prospective two-dimensional echocardiographic evaluation of left ventricular thrombus and embolism after acute myocardial infarction. *J Am Coll Cardiol* 1989, 13:554-64.
23. Heik CW, Kupper W, Hamm C, Bleifeld W, Koschyk DH, Walters D, Chen C. Evidence of high dose intravenous heparin for treatment of left ventricular thrombi with high embolic risk. *J Am Coll Cardiol* 1994, 24:1305-09.
24. Antman EM, Anbe DT, Armstrong PW, Bates ER, Green LA, Hand M, Hochman JS, Krumholz HM, Kushner FG, Lamas GA, Mullany CJ, Ornato JP, Pearle DL, Sloan MA, Smith SC. ACC/AHA guidelines for the management of patients with ST-elevation myocardial infarction: a report of the American College of Cardiology/American Heart Association Task Force on Practice Guidelines (Committee to Revise the 1999 Guidelines for the Management of Patients with Acute Myocardial Infarction) *Circulation* 2004, 110(9):e82-e292.
25. Kontny F, Dale J, Abildgaard U, Hegrenaes L, Lem P, Morstol T. Adverse effect of warfarin in acute myocardial infarction: increased left ventricular thrombus formation in patients not treated with high dose heparin. *Eur Heart J* 1993, 14:1040-1043.
26. Weiss P, Soff GA, Halkin H, Seligsohn U. Decline of proteins C and S and factors II, VII, IX and X during the initiation of warfarin therapy. *Thromb Res* 1987, 45: 783-90.
27. D'Angelo A, Vigano-D'Angelo S, Esmon CT, Comp PC. Acquired deficiencies of protein. S. *J Clin Invest* 1988, 81: 1445-54.
28. Moe T, Teien D, Karp K, Eriksson P. Left ventricular thrombosis after anterior myocardial infarction with and without thrombolytic treatment. *J Intern Med* 1995, 237:563-9.
29. Moe T, Teien DE, Karp KH, Eriksson P. Dynamics of left ventricular thrombi in patients with acute anterior myocardial infarction treated with thrombolytics. *Coron Artery Dis* 1995, 6:703-7.
30. Vecchio C, Chiarella F, Lupi G, Bellotti P, Domenicucci S. Left ventricular thrombus in anterior acute myocardial infarction after Thrombolysis - a GISSI-2 connected study. *Circulation* 1991, 84:512-519.
31. Abassade P, Lung B, Baudouy PY, Vuong PN, Valleteau de Moulliac M. Bilateral renal embolism during thrombolysis with tissue plasminogen activator in a patient with a left ventricular thrombus. *Arch Mai Coeur Vaiss* 1991, 84: 583-5.
32. Hochman JS, Lamas GA, Buller CE, Dzavik V, Reynolds HR, Abramsky SJ, Ruzyllo W, Maggioni AP, White H,



Sadowski Z, Carvalho AC, Rankin JM, Renkin JP, Steg PG, Mascette AM, Sopko G, Pfisterer ME, Leor J, Fridrich V, Mark DB, Knatterud GL. Coronary intervention for persistent occlusion after myocardial infarction. N Engl J Med 2006, 355:2395-407.

#### **ACKNOWLEDGEMENTS**

We acknowledge and thank Ms. Theresa Lindo for her kind assistance in preparing the pictures.

#### **PEER REVIEW**

Not commissioned. Externally peer reviewed.

#### **CONFLICTS OF INTEREST**

The authors declare that they have no competing interests.

#### **FUNDING**

None

#### **PATIENT CONSENT**

The authors, CR Potu, DS Baugh, EE Tulloch-Reid, EC Madu declare that:

1. They have obtained written, informed consent for the publication of the details relating to the patient in this report.
2. All possible steps have been taken to safeguard the identity of the patient(s).
3. This submission is compliant with the requirements of local research ethics committees.